
CASE REPORT

Clinical Implications of Erb-B2 Receptor Tyrosine Kinase 2 S310 Mutations in Non–Small-Cell Lung Cancer: Two Case Reports

Q Du, TY Kam, MW Yeung

Department of Clinical Oncology, Pamela Youde Nethersole Eastern Hospital, Hong Kong SAR, China

INTRODUCTION

Alterations to Erb-B2 receptor tyrosine kinase 2 (ERBB2) have been reported in approximately 1% to 4% of patients with non–small-cell lung cancer (NSCLC).^{1,2} Several somatic mutations associated with ERBB2 have been identified, with the most prevalent subtype being in-frame insertion in exon 20, located in the tyrosine kinase domain (TKD) of the human epidermal growth factor receptor 2 (HER2) protein, and accounting for 50% to 90% of cases.^{3–6} Other mutations such as the ERBB2 exon 8 mutation (S310) in the extracellular domain (ECD) have been infrequently reported (11% among patients with ERBB2 mutation) and remain underinvestigated.^{3,4} The latest National Comprehensive Cancer Network guideline version 2024 recommends antibody–drug conjugates (ADCs) of trastuzumab deruxtecan (T-DXd) and ado-trastuzumab emtansine (T-DM1) for ERBB2-mutant NSCLC patients progressing on platinum-based chemotherapy

with or without immunotherapy.⁷ The recommendation for T-DXd is primarily based on the DESTINY-Lung01 and DESTINY-Lung02 studies that demonstrated a promising overall response rate, duration of response (DOR), overall survival, and favourable toxicity profile.^{7,8} It is noteworthy that most patients recruited in these two studies exhibited ERBB2 mutations located in the TKD (93%–100%).^{8,9} Only a small proportion of patients (2.9%, n = 3) in the DESTINY-Lung02 study presented ERBB2 exon 8 substitutions on the ECD.⁹ To date, reports on the efficacy of ADCs on the ERBB2 S310 mutation remain scarce.³ We present two patients with ERBB2 S310 mutations in different clinical scenarios: the first had a de novo ERBB2 S310F mutation on diagnosis; the second showed concurrent ERBB2 S310Y and epidermal growth factor receptor (EGFR) L858R mutations, and MET amplification upon progression on first-line EGFR tyrosine kinase inhibitor (TKI) therapy.

Correspondence: Dr Q Du, Department of Clinical Oncology, Pamela Youde Nethersole Eastern Hospital, Hong Kong SAR, China
Email: dq083@ha.org.hk

Submitted: 4 January 2024; Accepted: 10 July 2024. This version may differ from the final version when published in an issue.

Contributors: QD and TYK designed the study. QD acquired and analysed the data and drafted the manuscript. All authors critically revised the manuscript for important intellectual content. All authors had full access to the data, contributed to the study, approved the final version for publication, and take responsibility for its accuracy and integrity.

Conflicts of Interest: All authors have disclosed no conflicts of interest.

Funding/Support: This study received no specific grant from any funding agency in the public, commercial, or not-for-profit sectors.

Data Availability: All data generated or analysed during the present study are available from the corresponding author on reasonable request.

Ethics Approval: The patients were treated in accordance with the Declaration of Helsinki. Informed consent for publication of the case reports was obtained from the patient and the patient's family for Case 1 and Case 2, respectively.

Supplementary Material: The supplementary material was provided by the authors and some information may not have been peer reviewed. Any opinions or recommendations discussed are solely those of the author(s) and are not endorsed by the Hong Kong College of Radiologists. The Hong Kong College of Radiologists disclaims all liability and responsibility arising from any reliance placed on the content. To view the file, please visit the journal online (<https://doi.org/10.12809/hkjr2417806>).

CASE PRESENTATIONS

Case 1

A 65-year-old male non-smoker with a medical history of radically treated early-stage intrahepatic cholangiocarcinoma and lung adenocarcinoma presented with back pain in May 2022. Magnetic resonance imaging (MRI) and positron emission tomography-computed tomography (PET-CT) of the whole spine in August 2022 revealed new lytic bone metastasis involving the L1-L2 vertebrae as well as right thoracic and mediastinal lymph node metastasis (Figure 1a-c). Pathology of the bone biopsy over the L2 vertebra confirmed metastasis of primary lung adenocarcinoma to the bone (thyroid transcription factor-1 positive). Tissue next-generation sequencing (NGS) using the OncoPrint Precision Assay GX (Thermo Fisher Scientific, Waltham [MA], US) revealed an ERBB2 S310F mutation, and the PD-L1 tumour proportion score was 0%.

First-line treatment with pemetrexed (500 mg/m² administered as an intravenous infusion on Day 1), carboplatin (AUC 5 administered as an intravenous infusion on Day 1), and pembrolizumab (200 mg administered as an intravenous infusion on Day 1) every 3 weeks was started in October 2022. PET-CT after cycle 4 in January 2023 revealed increased hypermetabolism in the right thoracic and mediastinal lymph nodes as well as several new hypermetabolic bone metastases involving the manubrium, ribs, pelvis, and spine (Figure 1d-f). Notably, the carcinoembryonic antigen (CEA) level decreased significantly from 198 ng/mL to 35.4 ng/mL within 3 months. Given the improved clinical symptoms, the overall impression was of immune unconfirmed progressive disease per iRECIST (Immune-based Response Evaluation Criteria in Solid Tumors) criteria,¹⁰ and two additional cycles of pemetrexed, carboplatin, and pembrolizumab were administered (online supplementary Table).

Subsequent PET-CT in March 2023 showed a partial response of the involved lymph nodes and largely unchanged bone metastasis (Figure 1g-i). Therefore, systemic treatment was switched to maintenance pemetrexed and pembrolizumab from cycle 7 in April 2023. Worsening back pain was reported and the CEA level had increased to 59.6 ng/mL in June 2023. Progress PET-CT in July 2023 confirmed disease progression of the right thoracic and mediastinal lymph nodes and bone metastases (Figure 1j-l). Second-line systemic treatment with T-DXd (5.4 mg/kg administered as an intravenous infusion on Day 1 every 3 weeks) was initiated. The

patient tolerated treatment well without significant side-effects. Serial chest X-rays did not show evidence of interstitial pneumonitis, even though he had previously undergone stereotactic body radiation therapy to the lung and immunotherapy. The CEA level rose to 214 ng/mL after four cycles of T-DXd. PET-CT in November 2023 showed disease progression with new hypermetabolic bone metastasis and mixed response of the previously seen multiple mixed lytic and sclerotic bone metastases, despite a partial response in the right thoracic and mediastinal lymph nodes (Figure 1m-o). The current plan is for the patient to receive third-line docetaxel (online supplementary Table).

Case 2

A 79-year-old male non-smoker presented with left hip pain in November 2022. PET-CT and MRI of the brain revealed a left lower lobe lung tumour with pleural, lymph node, liver, and bone metastases (Figure 2a-c). Pathology of lung biopsy indicated primary adenosquamous carcinoma with lung (both thyroid transcription factor-1 and p40 positive). Conventional tissue polymerase chain reaction via the Idylla platform (Biocartis, Mechelen, Belgium) revealed an EGFR L858R mutation. The patient commenced EGFR TKI erlotinib (150 mg daily) in December 2022 and CEA level had decreased from baseline 111.4 ng/mL to 33.6 ng/mL by March 2023 (online supplementary Table). The patient tolerated treatment well except for a grade 1 skin reaction and diarrhoea with reference to the CTCAE (Common Terminology Criteria for Adverse Events) version 5.0.¹¹

Worsening bone pain and deranged liver function were reported in March 2023. The EGFR TKI was switched to osimertinib due to the impaired liver function. CEA level rapidly increased from 33.6 ng/mL to 563 ng/mL from March to April 2023. PET-CT showed progression of the primary lung tumour in the left lower lobe and mixed response in the liver and bone with new emerging metastases (Figure 2d-f). Liquid NGS through the LiquidHALLMARK test (Lucence, Alto [CA], US) in March 2023 revealed EGFR L858R and TP53 S215G mutations, while EGFR T790M was negative. Pathology of the liver biopsy at the progressive site in April 2023 revealed non-small-cell carcinoma, and subsequent conventional polymerase chain reaction found only EGFR L858R mutation, without T790M mutation. Due to the rapid progression on EGFR TKI and the absence of T790M mutation in both liquid and tissue biopsies, the patient was prescribed one cycle of paclitaxel

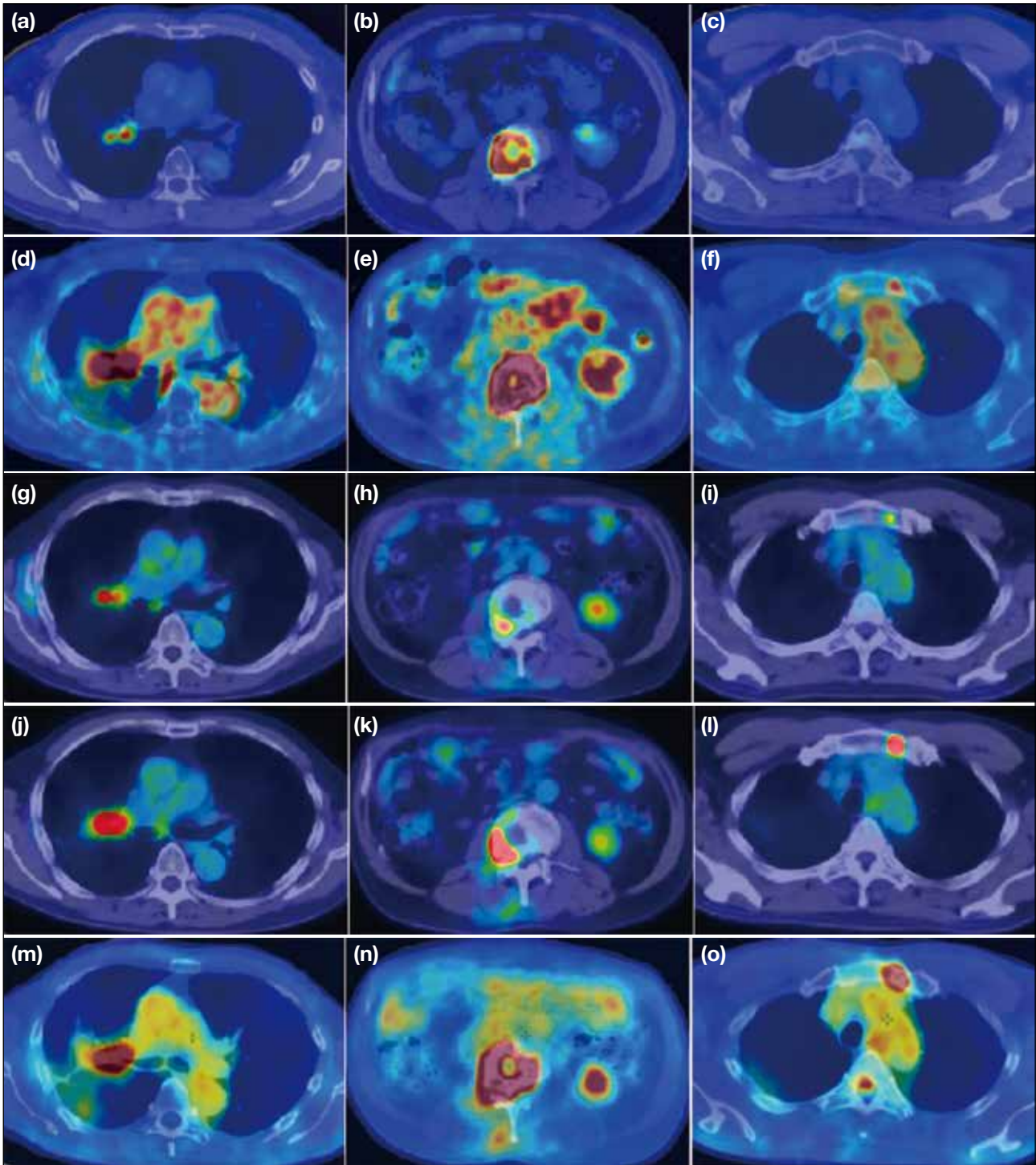


Figure 1. Case 1. Serial positron emission tomography–computed tomography scans at baseline and following first and subsequent lines of systemic treatment. (a) Right thoracic lymph node metastasis, (b) L2 bone metastasis and (c) manubrium bone metastasis at baseline (August 2022). (d) Right thoracic lymph node metastasis, (e) L2 bone metastasis and (f) manubrium bone metastasis after cycle 4 pemetrexed/carboplatin/pembrolizumab (January 2023). (g) Right thoracic lymph node metastasis, (h) L2 bone metastasis and (i) manubrium bone metastasis after cycle 6 pemetrexed/carboplatin/pembrolizumab (March 2023). (j) Right thoracic lymph node metastasis, (k) L2 bone metastasis and (l) manubrium bone metastasis after cycle 9 maintenance pemetrexed/pembrolizumab (July 2023). (m) Right thoracic lymph node metastasis, (n) L2 bone metastasis and (o) manubrium bone metastasis after cycle 4 trastuzumab deruxtecan (November 2023).

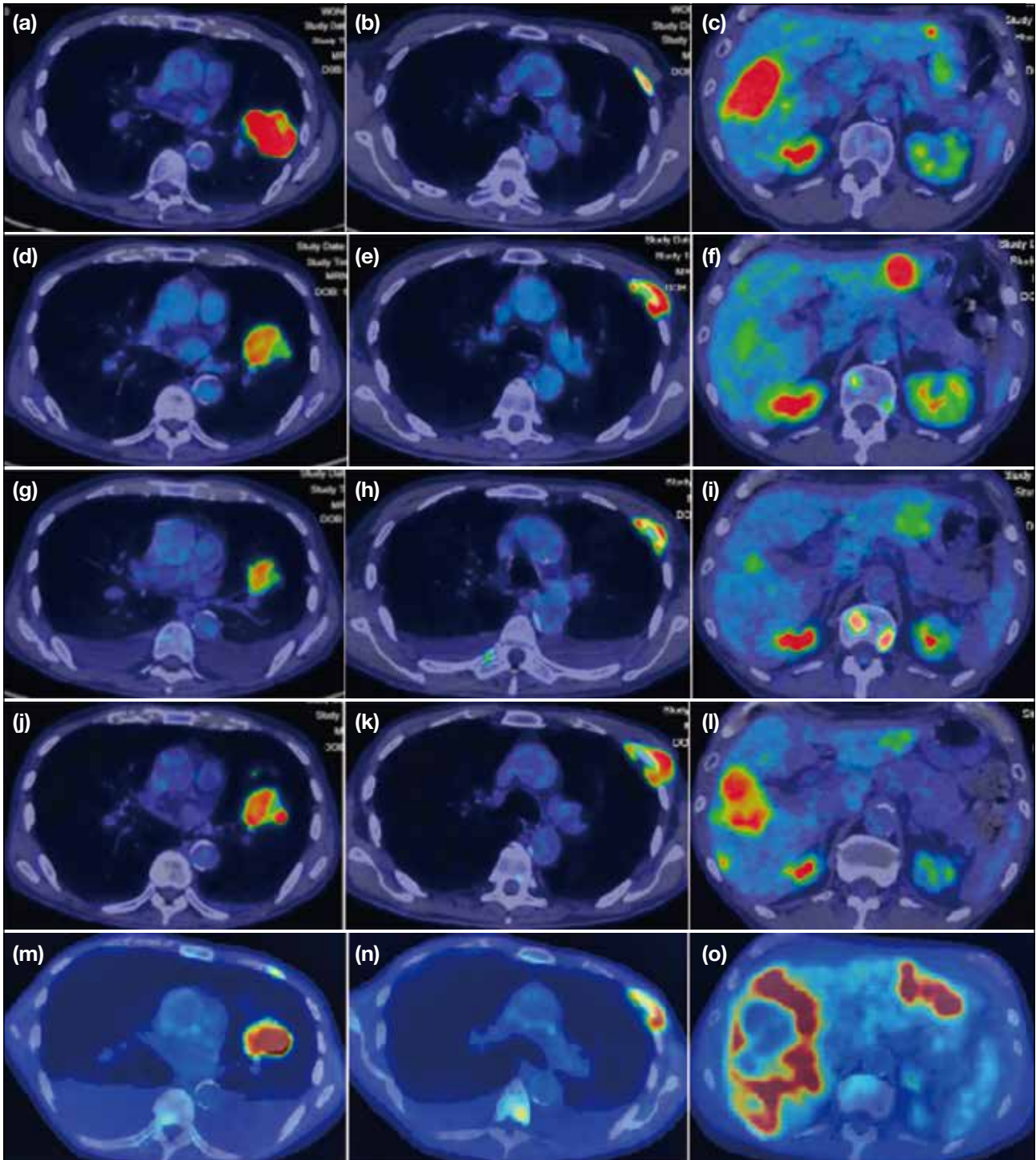


Figure 2. Case 2. Serial positron emission tomography–computed tomography scans at baseline and following first and subsequent lines of systemic treatment. (a) Primary lung tumour in the left lower lobe, (b) left lower rib metastasis and (c) liver metastasis at baseline (November 2022). (d) Primary lung tumour in the left lower lobe, (e) left lower rib metastasis and (f) liver metastasis after 4 months of erlotinib (March 2023). (g) Primary lung tumour in the left lower lobe, (h) left lower rib metastasis and (i) liver metastasis after cycle 1 paclitaxel/carboplatin (May 2023). (j) Primary lung tumour in the left lower lobe, (k) left lower rib metastasis and (l) liver metastasis after 3 months of osimertinib/tepotinib (August 2023). (m) Primary lung tumour in the left lower lobe, (n) left lower rib metastasis and (o) liver metastasis after cycle 2 trastuzumab deruxtecan (October 2023).

(175 mg/m² × 70% administered as an intravenous infusion on Day 1) and carboplatin (AUC 5 × 70% administered as an intravenous infusion on Day 1) in early May 2023 (Figure 2g-i). Nonetheless the treatment course was complicated by non-neutropenic fever, malaise, and gastrointestinal side-effects despite a dose reduction to 70% of the full dose. Therefore, tissue NGS from the liver biopsy specimen using ACT Precis Thorax (ACT Genomics, Taiwan) was conducted, revealing an EGFR L858R mutation, *MET* amplification, and ERBB2 S310Y mutation. Osimertinib (80 mg daily) and tepotinib (450 mg daily) were started in May 2023 at the patient's own expense (online supplementary Table).

The patient experienced grade 1 vomiting, transaminitis, lower limb oedema and grade 2 diarrhoea with reference to CTCAE version 5.0¹¹ during treatment, leading to a dose reduction of tepotinib to 225 mg daily in June 2023. CEA level initially decreased from 969 ng/mL to 607 ng/mL from May to July 2023 but rebounded to 1170 ng/mL in August 2023. PET-CT confirmed further disease progression of lung, pleural, liver, and bone metastases (Figure 2j-l). Given the previous suboptimal tolerance to chemotherapy and detection of the ERBB2 S310Y mutation by tissue NGS upon progression, T-DXd (5.4 mg/kg administered as an intravenous infusion every 3 weeks) was started in August 2023 as a self-financed medication. CEA level decreased from 1170 ng/mL to 550 ng/mL within the initial 2 months. Nonetheless the patient experienced recurrent non-neutropenic fever and required repeated courses of antibiotics and naproxen for possible sepsis and tumour fever. Serial chest X-rays did not suggest definite pneumonitis changes. PET-CT after two cycles of T-DXd showed disease progression in the liver with new emerging metastasis and superimposed infection (Figure 2m-o). In view of the suboptimal performance status and rapidly progressing disease, symptomatic care was initiated. Unfortunately, the patient passed away in November 2023 (online supplementary Table).

DISCUSSION

Data indicated that patients with *ERBB2* mutations exhibit a favourable response to first-line immunotherapy in combination with chemotherapy, with an overall response rate up to 52% and a median progression-free survival of 6 months.¹² Nonetheless most of these studies focused on patients with ERBB2 exon 20 insertion (66%), while patients with ERBB2 S310 mutations accounted for only 13% of the studied population.¹² In Case 1 with primary adenocarcinoma of lung harbouring de novo

ERBB2 S310F mutation, the efficacy of pemetrexed, carboplatin and pembrolizumab was maintained with the DOR up to 7 months, consistent with the currently available data.¹² The National Comprehensive Cancer Network guideline recommends ADCs for patients with ERBB2-mutant NSCLC after failure of first-line platinum-based chemotherapy with or without immunotherapy.⁷ To date, the clinical treatment response to ADCs specific to the S310 mutations have been rarely reported. A phase II basket trial reported two patients with the S310F mutation, with or without concurrent *ERBB2* amplification, who achieved a partial response or stable disease, respectively, to T-DM1.¹³ In our cases, Case 1 failed to exhibit a clinically meaningful response after four cycles of T-DXd. This may have been due to genuine treatment failure although another explanation could be tumour heterogeneity since the progress PET-CT indicated a partial response of lymph node metastasis but frank progression of bone metastasis (Figure 1).

It is hypothesised that the ERBB2 S310 mutation triggers hydrophobic interactions and non-covalent dimerisation, activating the downstream signalling pathway,¹⁴ thereby playing a pivotal role in oncogenesis as a driver mutation. The oncogenic de novo *ERBB2* mutations in NSCLC are believed to be mutually exclusive with other driver genes.¹⁵ Nonetheless other studies and case series have shown a minority of NSCLCs harbouring both *EGFR* and *ERBB2* alterations (0.46%),⁵ with a significantly higher frequency in the non-TKD S310 locus.^{15,16} It is speculated that patients treated with EGFR TKIs have compensated by developing ERBB2 ECD mutation bypassing *EGFR* to continue on the mitogen-activated protein kinase signalling pathway,⁵ driving resistance to EGFR TKIs with associated poor survival. In Case 2 with EGFR-mutant adenosquamous lung carcinoma demonstrating ERBB2 S310Y and *MET* amplification upon progression on first-line EGFR TKI, there were short progression-free intervals of 3 to 4 months on first-line EGFR TKI and the subsequent combination of EGFR/*MET* inhibitors, evidence that ERBB2 S310 may be a poor predictive and prognostic factor. Despite two cycles of T-DXd upon progression on TKIs, the patient continued to experience rapid disease progression with no clinically meaningful response (online supplementary Table). This may have been due to tumour heterogeneity given the mixed histology of adenosquamous carcinoma. Another plausible explanation is that the ERBB2 S310 mutation may mediate resistance to EGFR TKIs, rather than playing an oncogenic role, thereby rendering HER2-targeting therapy alone ineffective. Moreover,

the concurrent mutation of *EGFR* in the ERBB2-altered NSCLC may also impair the efficacy of anti-HER2 agents.¹⁵ Therefore, concomitant treatment of EGFR TKIs and an HER2-targeted agent may be a promising therapeutic strategy. Jia et al¹⁷ reported a patient with Li-Fraumeni syndrome and chemotherapy-refractory metastatic lung adenocarcinoma harbouring EGFR L858R and ERBB2 S310F mutations treated with a dual EGFR/ERBB2 inhibitor, afatinib. A complete response was achieved and maintained after 12 months.¹⁷ Nevertheless further investigations are needed to provide the rationale in these clinical settings.¹⁵

CONCLUSION

These two cases demonstrate that de novo ERBB2 S310 mutations and concurrent EGFR and ERBB2 S310 mutations did not yield a clinically meaningful response to T-DXd. The co-occurrence of ERBB2 S310 mutations with *EGFR±MET* amplification resulted in short DOR following the EGFR±MET inhibitors. This supports the association of ERBB2 S310 alterations with unfavourable clinical outcomes in NSCLC. Given the scarcity of studies focused on ERBB2 S310 mutations, it is essential to continue gathering valuable clinical data on these disease entities to enable real-world outcomes analysis.⁵

REFERENCES

- Mazieres J, Peters S, Lepage B, Cortot AB, Barlesi F, Beau-Faller M, et al. Lung cancer that harbors an *HER2* mutation: epidemiologic characteristics and therapeutic perspectives. *J Clin Oncol*. 2013;31:1997-2003.
- Zheng Y, Shen G, Zhang C, Huo X, Xin Y, Fang Q, et al. Efficacy of anti-HER2 drugs in the treatment of patients with HER2-mutated cancers: a systematic review and meta-analysis. *Clin Exp Med*. 2023;23:3205-16.
- Wang J, Wen Y, Ding G, Ding P, Zhang L, Liu J, et al. Efficacy generated by afatinib in a lung adenocarcinoma patient harboring HER2 S310Y mutation. *Cancer Biol Ther*. 2018;19:450-3.
- Jebbink M, de Langen AJ, Boelens MC, Monkhorst K, Smit EF. The force of HER2—a druggable target in NSCLC? *Cancer Treat Rev*. 2020;86:101996.
- Nagasaka M, Singh V, Baca Y, Sukari A, Kim C, Mamdani H, et al. The effects of *HER2* alterations in EGFR mutant non-small cell lung cancer. *Clin Lung Cancer*. 2022;23:52-9.
- Loeffler E, Ancel J, Dalstein V, Deslée G, Polette M, Nawrocki-Raby B. *HER2* alterations in non-small cell lung cancer: biologicoclinical consequences and interest in therapeutic strategies. *Life (Basel)*. 2023;14:64.
- National Comprehensive Cancer Network. NCCN Guidelines. Guidelines for patients: non-small cell lung cancer. Available from: <https://www.nccn.org/guidelines/guidelines-detail?category=1&id=1450>. Accessed 22 Nov 2024.
- Li BT, Smit EF, Goto Y, Nakagawa K, Udagawa H, Mazières J, et al. Trastuzumab deruxtecan in HER2-mutant non-small-cell lung cancer. *N Engl J Med*. 2022;386:241-51.
- Goto K, Goto Y, Kubo T, Ninomiya K, Kim SW, Planchard D, et al. Trastuzumab deruxtecan in patients with HER2-mutant metastatic non-small-cell lung cancer: primary results from the randomized, phase II DESTINY-Lung02 trial. *J Clin Oncol*. 2023;41:4852-63.
- Seymour L, Bogaerts J, Perrone A, Ford R, Schwartz LH, Mandrekar S, et al. iRECIST: guidelines for response criteria for use in trials testing immunotherapeutics. *Lancet Oncol*. 2017;18:e143-52.
- United States Department of Health and Human Services. Common Terminology Criteria for Adverse Events (CTCAE) Version 5.0. 2017 November 27. Available from: https://ctep.cancer.gov/protocoldevelopment/electronic_applications/docs/CTCAE_v5_Quick_Reference_5x7.pdf. Accessed 29 Nov 2024.
- Saalfeld FC, Wenzel C, Christopoulos P, Merkelbach-Bruse S, Reissig TM, Laßmann S, et al. Efficacy of immune checkpoint inhibitors alone or in combination with chemotherapy in NSCLC harboring *ERBB2* mutations. *J Thorac Oncol*. 2021;16:1952-8.
- Li BT, Shen R, Buonocore D, Olah ZT, Ni A, Ginsberg MS, et al. Ado-trastuzumab emtansine for patients with HER2-mutant lung cancers: results from a phase II basket trial. *J Clin Oncol*. 2018;36:2532-7.
- Greulich H, Kaplan B, Mertins P, Chen TH, Tanaka KE, Yun CH, et al. Functional analysis of receptor tyrosine kinase mutations in lung cancer identifies oncogenic extracellular domain mutations of *ERBB2*. *Proc Natl Acad Sci U S A*. 2012;109:14476-81.
- Yu X, Ji X, Su C. HER2-altered non-small cell lung cancer: biology, clinicopathologic features, and emerging therapies. *Front Oncol*. 2022;12:860313.
- Wei XW, Gao X, Zhang XC, Yang JJ, Chen ZH, Wu YL, et al. Mutational landscape and characteristics of *ERBB2* in non-small cell lung cancer. *Thorac Cancer*. 2020;11:1512-21.
- Jia Y, Ali SM, Saad S, Chan CA, Miller VA, Halmos B. Successful treatment of a patient with Li-Fraumeni syndrome and metastatic lung adenocarcinoma harboring synchronous EGFR L858R and ERBB2 extracellular domain S310F mutations with the pan-HER inhibitor afatinib. *Cancer Biol Ther*. 2014;15:970-4.