J HK Coll Radiol 2003;6:144-151

ORIGINAL ARTICLE

Correlation of Clinical Presentation, Radiography, and Magnetic Resonance Imaging for Low Back Pain — a Preliminary Survey

PY Yong, NAA Alias, IL Shuaib

Department of Radiology, Hospital Universiti Sains Malaysia, Malaysia

ABSTRACT

Purpose: *To determine the correlation between clinical presentation, plain radiographic signs, and magnetic resonance imaging of the lumbosacral spine for patients with low back pain.*

Patients and Methods: *Fifty seven patients were included in this study and their clinical presentation, plain radiographs and magnetic resonance findings were reviewed and correlated.*

Results: *Sensory deficit predicts the level of spinal stenosis. Linear correlation was observed between age and number of disc degeneration ($r = 0.756$). No significant correlation was noted between clinical presentation and disc herniation, nerve root compression, or spinal stenosis ($p > 0.025$). Age, duration of pain, and sciatica were significant predictors of stenosis ($p < 0.05$). Posterior disc height of less than 6 mm correlated significantly with root compression ($p < 0.001$) and spinal stenosis ($p = 0.015$). Significant correlation was observed between posterior osteophytes, end plate sclerosis and irregularity, vacuum phenomena, facet arthropathy, spondylolysis and spondylolisthesis with disc herniation, root compression, and spinal stenosis ($p < 0.025$). Plain lumbosacral radiographs were sensitive but not specific for the investigation of low back pain (sensitivity, 92.7%).*

Conclusion: *This was a preliminary survey with a small sample size, but may generate some useful data for future study with a larger number of patients.*

Key Words: *Low back pain, Lumbosacral region, Magnetic resonance imaging, X-ray*

INTRODUCTION

Low back pain is one of the common causes for consultation in accident and emergency departments, clinics, and hospitals. Approximately 60% to 80% of all adults will develop low back pain sometime in their life.[1] A vast spectrum of disease and pathology is known to cause pain. Yet despite extensive and costly investigations, the cause of low back pain will sometimes remain unknown.

Good history taking and thorough physical examination are essential for making a diagnosis of the cause of low back pain. Radiological imaging can be regarded as the most important investigation and it is essential for the diagnosis, pre-surgical evaluation and follow-up of patients with low back pain. Plain radiography, myelography, and conventional and computed tomography (CT) have traditionally been used to identify morphological changes in the discovertebral unit. Recent advances in magnetic resonance imaging (MRI) have dramatically improved the ability to evaluate the spinal canal and neural structures. It also has the potential to provide unique biochemical and physiological information. Ross and Modic found an 82.6% accuracy between MRI and surgical findings for the type and location of the disease.[2]

Compared with conventional imaging, MRI of the lumbosacral spine gives higher yield in the investigation of low back pain, particularly in terms of disc degeneration. However, due to the relatively high cost of MRI, a cost-effective diagnostic plan is necessary for the management of patients with low back pain. The correlation between clinical presentation, plain radiographic signs and MRI findings should also be made

Correspondence: *Dr PY Yong , Yeong Specialist X-ray Clinic and Pusat MRI, 50 Medical Specialist Centre, Jalan Pudu, 55100 Kuala Lumpur, Malaysia.*
Tel: (603) 2078 9424/2072 1750; Fax: (603) 2072 1493;
E-mail: pyyong@hotmail.com

Submitted: 13 May 2002; Accepted: 27 June 2003.

well known so that maximum benefit can be achieved from MRI of the lumbosacral spine. Thus, the purpose of this study was to investigate the correlation between clinical presentation, plain radiographic findings, and the MRI features in patients with low back pain.

PATIENTS AND METHODS

This study was performed between September 1999 and December 2000. Patients with known primary malignancy, recent spinal fracture within 3 months, lumbosacral spinal surgery, known infective spondylitis, congenital spinal anomaly, or systemic diseases involving the spine were excluded. A total of 63 consecutive patients referred for MRI for low back pain were analysed — 57 fulfilled the inclusion criteria.

Patients' personal data and presentation were obtained from the medical records. Neurological signs and symptoms were assessed by the referring physician. Plain lumbosacral radiographs included at least the standard anteroposterior and lateral views. The oblique views were not mandatory but, if available, they were also analysed. MRI was performed using Signa Horizon 1.0 Tesla LX Magnetic Resonance System (General Electric, Milwaukee, USA). Standard sequences included sagittal T1 FSE (T1 fast spin echo, TR 400 - 600 msec, TE minimum); sagittal T2 FSE (TR 3500 - 3800 msec, TE 120 - 130 msec); axial T2 FSE (TR 4000 - 5000 msec, TE 85 - 100 msec) and axial Proton Density FSE (TR 2000 msec, TE minimum). For all sequences, 4 mm slice thickness was used. The interval between plain radiograph and MRI was less than 3 months.

The plain radiographs and MRI images were interpreted by a radiologist with an interest in musculoskeletal radiology. Plain radiographs and MR images for each patient were shown and read at different times to prevent bias and the radiologist was blinded to the patients' personal data and clinical presentations.

For assessment of plain radiographic signs, posterior disc height was measured from the most posteroinferior point of the vertebral body above to the most posterosuperior point of the vertebral body below.[3] Interpedicular distance was taken as the shortest distance between the inner convex cortical surfaces of the opposing segmental pedicles in anteroposterior view.[4] This was considered to be narrowed when there was <21 mm for L1 to L4 and <23 mm for L5. Sagittal canal measurement was measured on lateral view by Eisenstein's method.[4] The lumbar canal was considered stenosed when the sagittal canal was less than 15 mm. Spondylolisthesis was classified using Meyerding classification.[4]

For MR images, signal intensity of the intervertebral disc was assessed following the criteria used by Milette et al.[5] The brightest signal intensity observed on T2WI in the central four-fifths of D11-D12, D12-L1 and L1-L2 disc was considered the normal standard for each patient. High-intensity zone (HIZ) was defined as a high-intensity signal located in the substance of the posterior annulus fibrosus, clearly dissociated from the signal of the nucleus pulposus (Figure 1). Disc bulge was defined as diffuse disc extension beyond the adjacent vertebral body margins circumferentially (Figure 2). Disc protrusion was considered to be displacement of the nucleus pulposus through some of the fibres of annulus fibrosus, while remaining confined by the intact outermost fibres (Figure 3). Extrusion referred to a true herniated disc that had extended through all layers of the annulus, whereas a sequestrated disc was a fragment that was no longer in continuity with the parent disc

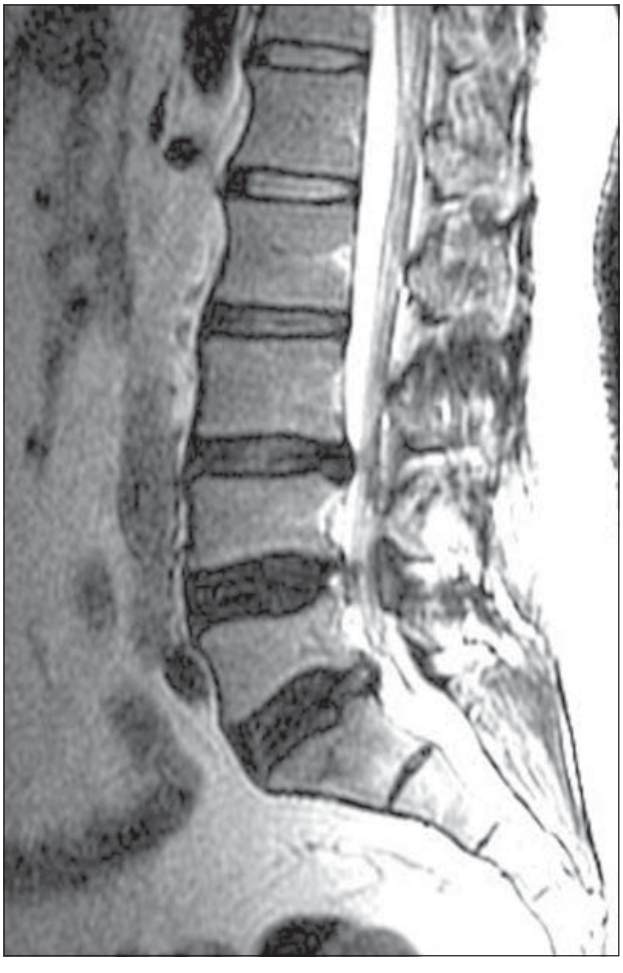

Figure 1. T2-weighted mid-sagittal image demonstrating high intensity zone in L5/S1 disc.

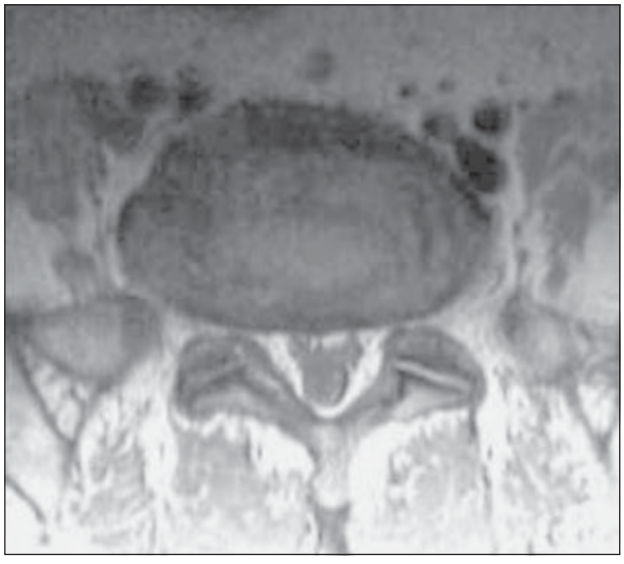

Figure 2. Proton-density axial image showing intervertebral disc bulge.

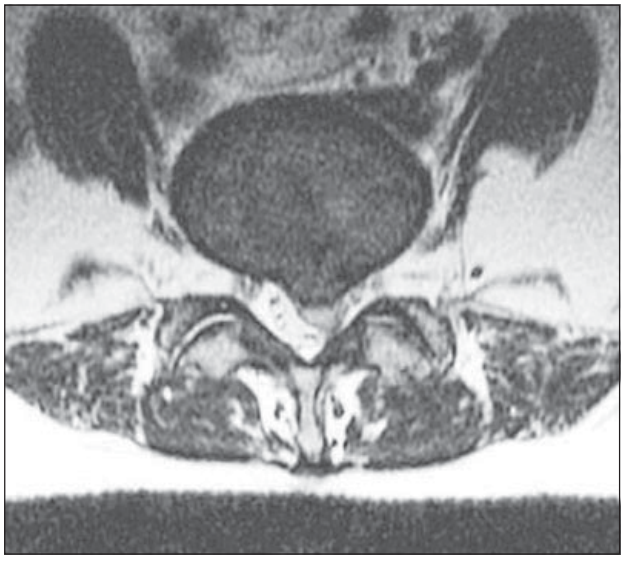

Figure 3. Axial T2-weighted image showing L5/S1 disc protrusion.

material.[6,7] Foraminal narrowing was measured at the foraminal segment of the radicular canal.[8] Normal measurement was taken as ≥4 mm. Ligamentum flavum was measured at the widest diameter on axial images. Hypertrophy was considered when it was ≥5 mm. Anteroposterior diameter of the canal was measured from the posterior margin of the intervertebral disc to the spinolaminar junction. It was considered stenosed when <11.5 mm.[6] End-plate changes were assessed using Modic classification.

Statistics

The data were analysed using the SPSS for Windows version 9.0 software program. MRI findings were grouped into 3 main outcomes of disc herniation, nerve root compression, and spinal stenosis. Correlation between clinical data and MRI findings were studied using Fisher's-exact or Chi square test. McNemar test was used to analyse the correlation between plain radiograph and MRI findings. For all 3 tests, α was taken as 0.05 (2-tailed). Thus, when the p value was <0.025, the results were significant.

A diagnostic test was done for plain lumbosacral radiograph using MRI as the reference standard. Multivariate analysis using binary logistic regression was performed to study the predictive value of clinical data with disc herniation, nerve root compression, and spinal stenosis. Correlation-regression study was used to determine the correlation between age and number of degenerated intervertebral discs confirmed by MRI.

RESULTS

Fifty seven patients were included in this study. Their ages ranged from 20 to 71 years (mean, 44.8 years; standard deviation, 12.69 years). Thirty five patients (61.4%) were men and 22 (38.6%) were women. The majority of patients were Malay (86%), 8.8% were Chinese, and 5.3% were Indian. The mean interval between plain radiograph and MRI was 18.9 days.

Thirty two patients (56.0%) presented with chronic low back pain of more than 3 months duration. Eighteen patients (32.0%) had subacute pain (1 week to 3 months and 7 had acute pain (less than 1 week). Sciatica was present in 33 patients (57.9%). Lower limb weakness occurred in 12 patients (21.1%) and 24 (42.1%) had lower limb numbness.

Physical examination revealed lumbosacral tenderness in 13 patients (22.8%), sensory deficit in 20 (35.1%), and motor deficit in 23 (40.4%). From the 20 patients who had sensory deficit, only 11 had nerve root compression on MRI. Of these 11 patients, 6 (54.5%) were found to have a corresponding level of sensory deficit and nerve root compression. For the remaining 5 patients (45.5%), although nerve root compression was present, the level did not correspond to the sensory deficit level detected during examination. Thirteen patients had both sensory deficit and confirmed spinal stenosis on MRI. For all these patients, the level of spinal stenosis was corresponding to the level of sensory deficit.

For plain radiograph findings (Figure 4), reduction of posterior intervertebral disc height (<6 mm) was the most frequent finding, seen in 82.5% of patients. This

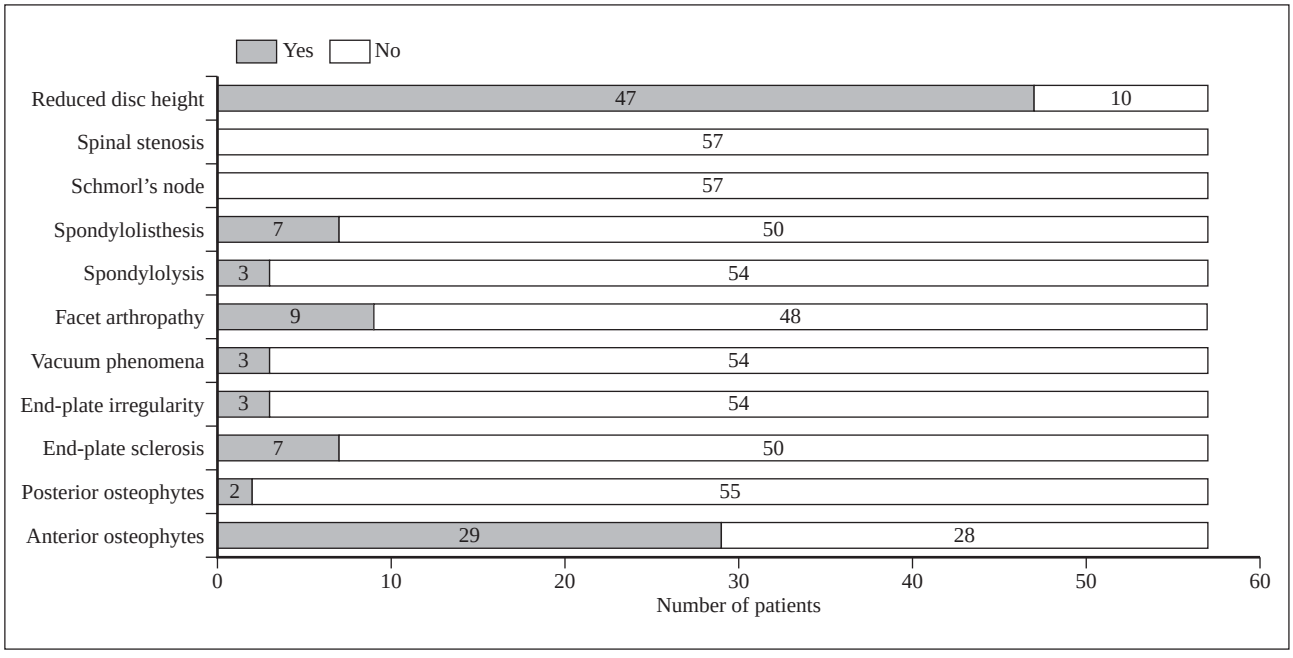

Figure 4. Bar chart showing frequency of various findings on plain radiograph.

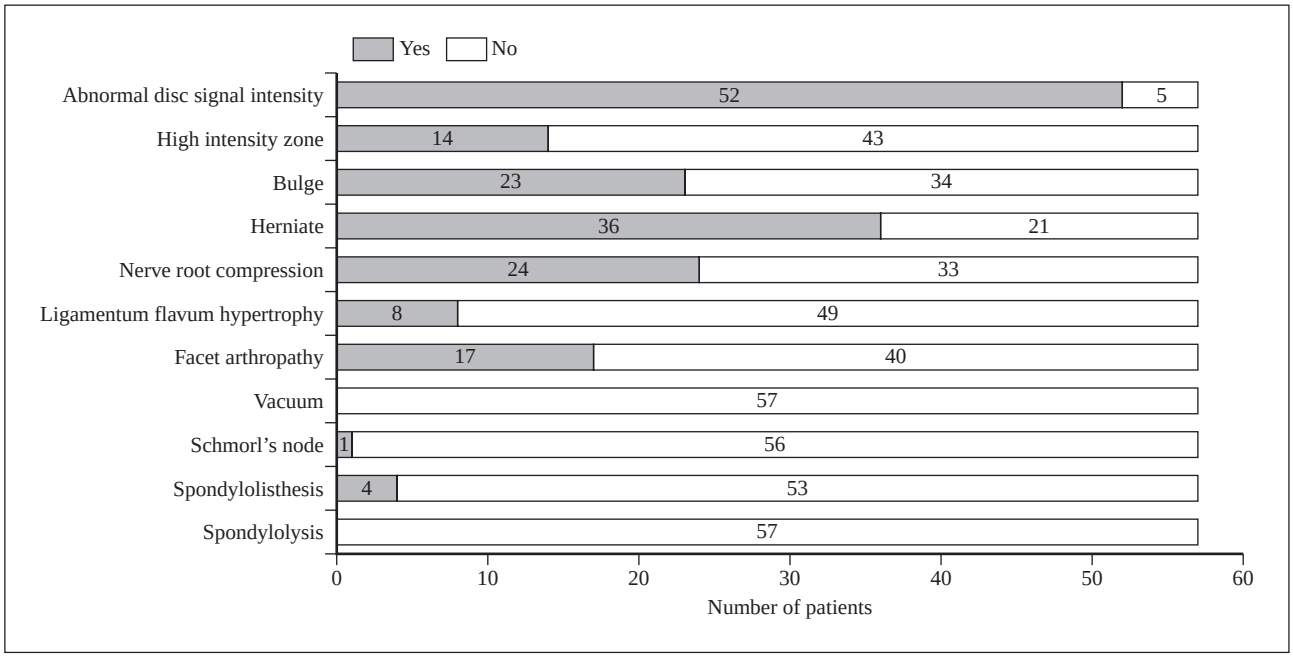

Figure 5. Frequency of various magnetic resonance imaging signs.

was followed by anterior osteophytes, which were present in 50.9% of patients. Posterior osteophytes were less common and were only present in 2 patients. Facet arthropathy occurred in 15.8% of patients, whereas spondylolisthesis was seen in 12.3%. End-plate sclerosis and irregularity was present in 7 and 3 patients, respectively. Vacuum phenomena and spondylolysis occurred in 3 patients each. None of the patients had Schmorl's nodes or spinal canal stenosis on plain radiograph.

On MRI (Figure 5), intervertebral disc degeneration was the most frequent finding, observed in 52 patients (91.2%). This was followed by intervertebral disc herniation, seen in 36 patients (63.2%). Of these 36 patients, 18 (50%) had protrusion alone and 7 (19.4%) had only extrusion. Ten patients (27.8%) had protrusion and extrusion and 1 patient (2.8%) had both protrusion and sequestration. Circumferential intervertebral disc bulge occurred in 40.4% of patients. Nerve root compression was present in 24 patients (42.1%). Seventeen patients

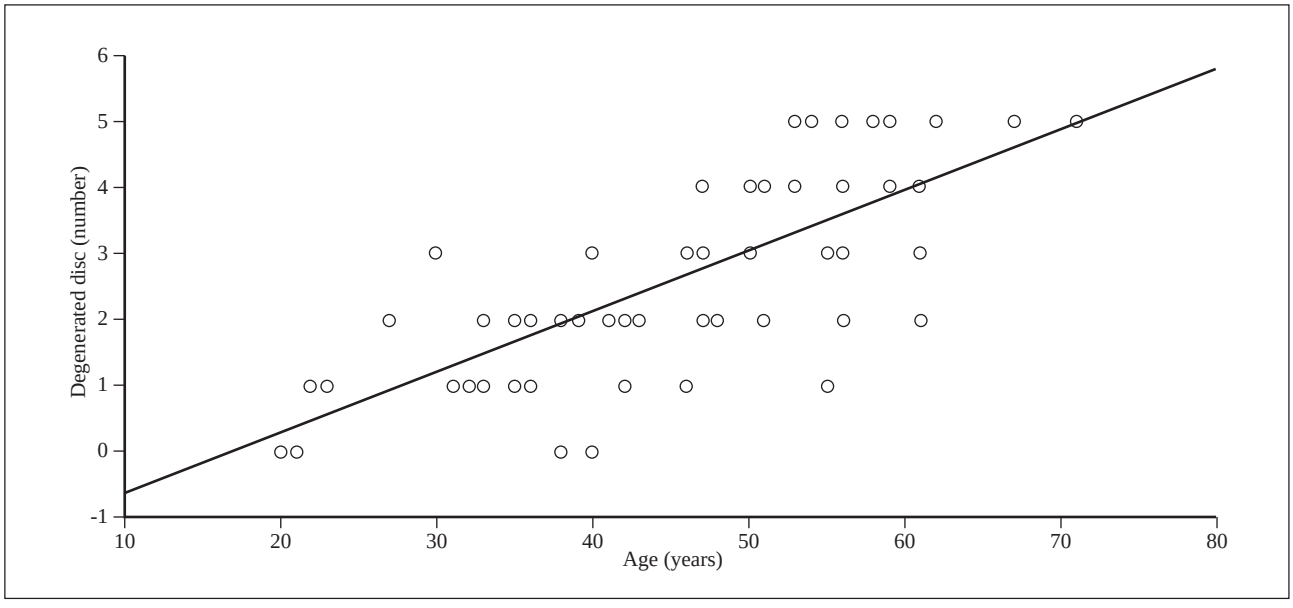

Figure 6. Scattered diagram showing linear correlation (r = 0.756) between age in years and number of degenerated intervertebral discs.

(29.8%) had facet arthropathy. HIZ, a finding indicating annular tear, was observed in 14 patients (24.6%). Eight of 57 patients (14.0%) manifested ligamentum flavum hypertrophy. Four patients (7.0%) had spondylolisthesis and 1 patient had Schmorl's nodes. None of the 57 patients had either vacuum phenomena or spondylolysis. The majority of the patients (80.7%) had normal end plates. Nine patients (15.7%) had type 2 changes. One had type 1 changes and the remaining 1 had type 3 changes. Spinal stenosis, in which the anteroposterior of the spinal canal was <11.5 mm was present in 34 patients (59.6%). Seventeen patients (29.8%) had exit foramina narrowing (<4.0 mm).

There was a good linear correlation (r = 0.756) between the age of the patient and the amount of intervertebral disc degeneration, as evidenced by loss of normal high signal intensity of the nucleus pulposus on T2-weighted MRI (Figure 6).

Using multivariate study, it was found that age, duration of pain, and sciatica were significantly correlated with spinal stenosis ($p < 0.05$) [Table 1]. However, multivariate study showed that the clinical data were not predictive of disc herniation and nerve root compression.

Comparing radiographic features with disc herniation, the p values for posterior osteophytes, end-plate sclerosis, end-plate irregularity, vacuum phenomena, facet arthropathy, spondylolysis, and spondylolisthesis were less than 0.025. As for nerve root compression and spinal stenosis, in addition to posterior osteophytes, end-plate sclerosis, end-plate irregularity, vacuum phenomena, facet arthropathy, and spondylolysis and spondylolisthesis, reduced intervertebral disc height was also found to be significant where $p < 0.025$. The sensitivity of plain radiograph was 92.7% and the positive predictive value was 96.2%.

Table 1. Multivariate analysis of the relation of clinical data with spinal stenosis.

	p Value	Odds ratio	95% Confidence interval
Age	0.027*	4.158	1.177-14.687
Duration of pain	0.034*	0.227	0.058-0.891
Sciatica	0.048*	3.776	1.011-14.100

* Binary logistic regression analysis — significant if p value <0.05.

DISCUSSION

Magnetic Resonance Imaging Findings

Degeneration of intervertebral disc was the most frequent feature observed in 91.2% of the patients. Radial annular tear, present as a focus of HIZ at the periphery of the disc was observed in 24.6% of the studied patients. This corresponds to a previous study by Aprill and Bogduk, which reported a 28% prevalence of HIZ in patients with back pain.[9] They also concluded that HIZ was highly specific and strongly predictive of a painful disc. It is believed that HIZ suggests the presence of an internal derangement of the disc and is the source of pain until proven otherwise. Schellhas et al found that HIZ is a reliable marker for a painful disc in those patients with low back pain or sciatica.[10] They also reported that if T2-weighted sequences are routinely

used, gadolinium is not required to demonstrate HIZ. Nevertheless, another study by Weishaupt et al showed that HIZ could commonly be seen in asymptomatic individuals younger than 50 years.[11]

MRI is recognised as being accurate for detecting intervertebral disc herniation. In addition, MRI has high accuracy in differentiating the subtype of disc herniation.[12] Forristall et al reported 90% accuracy for MRI compared with 78% for CT myelography.[13] Nevertheless, the detection of disc herniation need not necessarily explain the source of pain in those patients. A study by Jensen et al found that 52% of asymptomatic individuals had disc bulge and 28% had disc herniation.[14] These researchers also concluded that the prevalence of intervertebral disc bulges, but not protrusion, increased with age. Weishaupt et al also reported that disc bulge and protrusion are common findings in asymptomatic individuals younger than 50 years.[11] However, disc extrusion and sequestration were less common as extrusion was present in 3.7% of their patients and none of the patients had disc sequestration. Therefore, these researchers concluded that disc extrusion and sequestration were predictive of low back pain in symptomatic patients.

Nerve root compression is another finding predictive of low back pain. Boos et al suggested that neural compromise might have a more important role than intervertebral disc herniation in explaining low back pain.[15] In this study, 42.1% of patients were noted to have compression of at least 1 nerve root. Weishaupt et al found that the prevalence of end-plate abnormalities in asymptomatic patients was low (1.9%).[11] Thus, their results supported the hypothesis that end-plate abnormalities might be predictive of low back pain.

Clinical Data Versus Magnetic Resonance Imaging

In this study, good linear correlation was observed between age and number of degenerated discs ($r = 0.756$). This corresponds with the study by Cassar-Pullicino who showed that by the age of 50 years, 97% of individuals have degenerative disc.[12] Nevertheless, an abnormal disc signal need not necessarily be the cause of back pain. This is because more than 30% of asymptomatic individuals of varying ages have been noted to have disc degeneration.[16] However, the same study also reported that, in patients with low back pain, the more levels of degenerative discs, the higher the likelihood of being symptomatic. Another study by Boden et al showed that the abnormal lumbar intervertebral disc seen on MRI is most reliable when it is observed in symptomatic patients younger than 60 years.[17]

From the univariate analysis using Chi square test, there was no significant correlation between the age, duration of pain, presenting symptoms, or clinical signs with intervertebral disc herniation, nerve root compression, or spinal stenosis. This suggests that based on clinical findings alone, it is difficult to predict the MRI outcome. Nevertheless, using multivariate analysis, age, duration of pain, and presence or absence of sciatica were found to be significant predictors of spinal stenosis ($p < 0.05$).

Not many studies have examined the correlation between clinical presentation and the results of MRI for patients with low back pain. In a study of patients with intervertebral disc herniation by Vucetic et al, it was found that the strongest variables predicting the degree of herniation were duration of pain and progressive leg pain or sciatica.[18] Staiger et al reported that sciatica was 95% sensitive in predicting disc herniation.[19] Thus, these authors concluded that in the absence of sciatica, a clinically meaningful disc herniation is very unlikely. However, from this study, the author found that only 63.6% of patients with sciatica had disc herniation. On the other hand, in 15 patients who had disc herniation seen on MRI, there was no history of sciatica. In this group of patients, the possible explanation is that the degree of disc herniation was not severe enough to cause symptom of sciatica.

Plain Radiograph Versus Magnetic Resonance Imaging

Kappa statistic was applied to evaluate the agreement between plain lumbosacral radiograph and MRI. There was good agreement ($\kappa = 0.701$) between findings of spondylolisthesis for both the imaging modalities. For the correlation between end-plate sclerosis on plain radiograph and end-plate changes on MRI, only a fair correlation ($\kappa = 0.216$) was noted. The fatty degeneration in type 1 and vascularisation in type 2 end-plate changes are non-apparent on plain radiograph. Only type 3 changes, where there is presence of dense bone devoid of marrow, can be seen on plain radiograph as sclerosis. Thus, early end-plate marrow degeneration is better depicted on MRI than on plain radiograph.

Three patients had pars interarticularis defect on plain radiograph. However, none of these was seen in the MR images. In this study, the lumbosacral MRI were

performed according to the department protocol where axial images were obtained parallel to and through the intervertebral discs. Ulmer et al performed a study on MRI of lumbar spondylolysis.[20] They showed that pars interarticularis defect could be recognised as an area of decreased signal intensity on axial or sagittal T1 and T2-weighted images. If there is associated spondylolisthesis, a fat filled gap may be appreciated between the fragments of the pars interarticularis. However, these researchers also found that detection of spondylolysis on MRI might be difficult, especially when contiguous axial sections were not obtained. Thus, in future, for patients with suspicious pars interarticularis defects, the author would like to suggest contiguous axial sections to be done in addition to the sagittal images.

Using the McNemar statistic test, the author noted that posterior disc height of less than 6 mm has significant correlation with nerve root compression and spinal stenosis. Interestingly, with regards to disc herniation, there was no significant relationship with posterior disc height. As defined earlier, disc herniation is inclusive of intervertebral disc protrusion, extrusion and sequestration. The author believed that any of the 3 subtypes of herniation, if not severe, might not cause detectable reduction of the disc height in lateral lumbosacral radiograph. When reduction of posterior disc height is apparent on radiograph, the degree of herniation would have been severe enough to cause spinal stenosis and/or nerve root compression. Thus, when the posterior disc height is less than 6 mm in a symptomatic patient, MRI should be considered to evaluate the spinal canal and neural foramina.

Although more frequently observed, anterior osteophytes have no significant association with either disc herniation, nerve root compression or spinal stenosis. On the other hand, posterior osteophytes were found to be significantly associated with disc herniation, nerve root compression, and spinal stenosis. A study by Marchiori et al showed that osteophytic change was less sensitive and accurate to early inner disc degenerative change.[21] When osteophytes and reduced disc height were present together, a stronger prediction of degeneration was possible than when either finding was present alone. However, in that study, the correlation between osteophytosis and disc herniation, nerve root compression, or spinal stenosis was not included.

This study showed that both end-plate sclerosis and end-plate irregularity were very significantly related to disc herniation, nerve root compression, and spinal stenosis. The p value of both the changes was <0.001. Likewise, the vacuum phenomena, facet arthropathy, spondylolysis, and spondylolisthesis were also significantly correlated with disc herniation, nerve root compression, and spinal stenosis.

CONCLUSIONS

There was no significant correlation between clinical presentation and MRI findings of disc herniation, nerve root compression, and spinal stenosis. Nevertheless, age of patient, duration of pain, and sciatica could predict spinal stenosis. History taking and thorough physical examination are important in order to identify the group of patients who would benefit most from MRI. When a lesion is identified on MRI, it should be properly correlated and its clinical significance ascertained before being labelled as the source of back pain. Surgical intervention should only be contemplated after considering a patient's age, clinical symptoms, and signs together with MRI findings.

Plain lumbosacral radiograph was sensitive though not specific for the investigation of low back pain. Some of the radiographic features such as reduction of posterior intervertebral disc height, posterior osteophytes, spondylolisthesis, spondylolysis and end-plate changes correlated significantly with MRI findings of disc herniation, nerve root compression, and spinal stenosis. Although lumbosacral radiography carries the risk of radiation, it still has an important role in the management of low back pain.

This was a preliminary survey with a small sample size. The author hopes that this survey will generate some useful data in view of future study with a larger number of patients.

REFERENCES

1. Gaskill MF, Lukin R, Wiot JG. Lumbar disc disease and stenosis. Clin Radiol North Am 1991;29:735-764.
2. Ross JS, Modic MT. Current assessment of spinal degenerative disease with magnetic resonance imaging. Clin Ortho Rel Res 1992;279:68-81.
3. Hamanishi C. Schmorl's nodes on MRI: their incidence and clinical relevance. Spine 1994;19:450-453.
4. Yoshum TR, Rowe LJ. Essentials of skeletal radiology. Williams & Wilkins, 1996.
5. Milette PC, Fontaine S, Lepanto L, Cardinal E, Brenton G. Differentiating lumbar disc protrusion, disc bulges and discs with normal contour but abnormal signal intensity. Spine 1999;24:44-53.
6. Atlas SW. MRI of the brain and spine. New York: Lippincott-Raven; 1996.

7. Resnick D. Diagnosis of bone and joint disorders. Philadelphia: Saunders; 1995.
8. Grenier N, Kressel HY, Schiebler ML, Grossman RI, Dalinka MK. Normal and degenerative posterior spinal structures: MR imaging. Radiology 1987;165:517-525.
9. Aprill C, Bogduk N. High-intensity zone: a diagnostic sign of painful lumbar disc on magnetic resonance imaging. Br J Radiol 1992;65:361-369.
10. Schellhas KP, Pollei SR, Gundry CR, Heithoff KB. Lumbar disc high-intensity zone, correlation of magnetic resonance imaging and discography. Spine 1996;21:79-86.
11. Weishaupt D, Zanetti M, Hodler J, Boos N. MR imaging of the lumbar spine: prevalence of intervertebral disk extrusion and sequestration, nerve root compression, end plate abnormalities, and osteoarthritis of the facet joints in asymptomatic volunteers. Radiology 1998;209:661-666.
12. Cassar-Pullicino VN. MRI of the ageing and herniating intervertebral disc. Eur J Radiol 1998;27:214-228.
13. Forristall RM, Marsh HO, Pay NT. Magnetic resonance imaging and contrast CT of the lumbar spine. Comparison of diagnostic methods and correlation with surgical findings. Spine 1988;13: 1049-1054.
14. Jensen MC, Brant-Zawadzki MN, Obuchowski N, Modic MT, Malkasian D, Ross JS. Magnetic resonance imaging of the lumbar spine in people without back pain. N Engl J Med 1994;331: 69-73.
15. Boos N, Rieder R, Schade V, Spratt KF, Semmer N, Aebi M. The diagnostic accuracy of magnetic resonance imaging, work perception, and psychosocial factors in identifying symptomatic disc herniations. Spine 1995;20:2613-2625.
16. Buirski G, Silberstein M. The symptomatic lumbar disc in patients with low-back pain, magnetic resonance imaging appearances in both a symptomatic and control population. Spine 1993; 18:1808-1811.
17. Boden SD, Davis DO, Dina TS, Patronas NJ, Wiesel SW. Abnormal magnetic-resonance scans of the lumbar spine in asymptomatic subjects. The J Bone Joint Surg 1990;72A: 403-408.
18. Vucetic N, de Bri E, Svensson O. Clinical history in lumbar disc herniation. A prospective study in 160 patients. Acta Orthop Scand 1997;68:116-120.
19. Staiger TO, Paauw DS, Deyo RA, Jarvik JG. Imaging studies for acute low back pain, when and when not to order them. Postgrad Med 1999;105:161-172.
20. Ulmer JL, Mathews VP, Elster AD, Mark LP, Daniels DL, Mueller W. MR imaging of lumbar spondylolysis: the importance of ancillary observations. Am J Roentgenol 1997;169: 233-239.
21. Marchiori DM, McLean I, Firth R, Tatum R. A comparison of radiographic signs of degeneration to corresponding MRI signal intensities in the lumbar spine. J Manipulative Physiol Ther 1994;17:238-245.