Hong Kong J Radiol. 2015;18:243-52 | DOI: 10.12809/hkjr1515300

PICTORIAL ESSAY

Magnetic Resonance Imaging of Fistula-in-ano

CYH Chan, KYK Wong, SKY Kwok, WK Wong, KW Tang

Department of Radiology and Imaging, Queen Elizabeth Hospital, Jordan, Hong Kong

ABSTRACT

Fistula-in-ano is a highly devastating disease due to its high morbidity. In order to achieve excellent surgical outcome, preoperative evaluations are essential. Magnetic resonance imaging (MRI) allows high spatial resolution images and is highly accurate in delineating the type and extent of a perianal fistula. MRI has also been shown to markedly diminish recurrence by improving preoperative planning. Therefore, preoperative pelvic MRI has already become routine in the management of perianal fistula. Adequate knowledge of the relevant pelvic anatomy, pathophysiology, fistula classification, and their implications on the therapeutic options is the key for proper MRI assessment of perianal fistula. This pictorial essay discusses these topics.

Key Words: *Magnetic resonance imaging; Rectal fistula*

中文摘要

肛瘻的磁共振成像

陳彥豪、黃汝麒、敦啟欣、王旺根、鄧國穎

肛瘻是一種嚴重影響生活質量的疾病。要有優良的手術效果，術前評估至為關鍵。磁共振成像（MRI）有高空間分辨率，評估肛周瘻的類型和程度亦具高度準確性。MRI能改善術前計劃以減少復發，所以盆腔術前MRI已被納入常規程序當中。要正確評估肛周瘻的MRI，必須對相關的盆腔解剖、病理生理學、內瘻的分類，以及其對治療方案的影響有充分了解。本圖案綜述回顧討論相關內容。

INTRODUCTION

Fistula-in-ano is the most common form of perianal sepsis and is highly devastating due to its high morbidity. In order to achieve excellent surgical outcome, preoperative evaluations are essential. Magnetic resonance imaging (MRI) allows high spatial and contrast resolution images and is highly accurate in delineating the type and extent of perianal fistula. MRI has also been shown to markedly diminish recurrence by improving preoperative planning.[1,2] Therefore preoperative pelvic MRI has already become routine in the management of perianal fistula.

This pictorial essay aimed to highlight the relevant pelvic anatomy, pathophysiology, fistula classification, and important findings that should be included during

Correspondence: *Dr Cyrus YH Chan, Department of Radiology and Imaging, Queen Elizabeth Hospital, Jordan, Hong Kong. Email: cyhchan2007@yahoo.com.hk*

Submitted: 15 Jan 2015; Accepted: 2 Jun 2015.

MRI reporting.

ANATOMY

The anal canal commences at the level where the rectum passes through the levator ani muscles and ends at the anal verge (Figures 1 and 2). The upper border of the puborectalis muscle is regarded as the upper boundary of the anal canal. The anal canal is bounded by internal and external anal sphincters. The internal anal sphincter complex is the inferior continuation of circular smooth muscles of rectum, and is primarily responsible for involuntary resting anal tone; the external anal sphincter complex is the inferior continuation of the levator ani and puborectalis muscles, and is primarily responsible for voluntary anal tone when contracted.[3] The intersphincteric plane is the potential space, which contains predominantly fat, areolar tissue, and longitudinal muscle to separate the internal and external sphincters. The mucosal surface of the proximal anal canal is lined by longitudinal mucosal columns, known as the columns of Morgagni. The spaces between the columns are known as the crypts of Morgagni, which receive drainage from the anal glands. The dentate line is an important morphological landmark of the anal canal. It is located at the mid-anal canal level, where the squamous epithelium transforms into columnar epithelium. The dentate line is important during the development of perianal fistula. As the site where the anal glands empty into the anal canal, the dentate line is the level where most of the internal openings can be found. More peripherally, surrounding the anal sphincters are the ischioanal fossae.

Surgeons describe the openings and course of perianal fistula by referring to the anal clock (Figure 3), which is the view of the perineum with patients in the lithotomy position during fistula surgery. At 12 o'clock is the

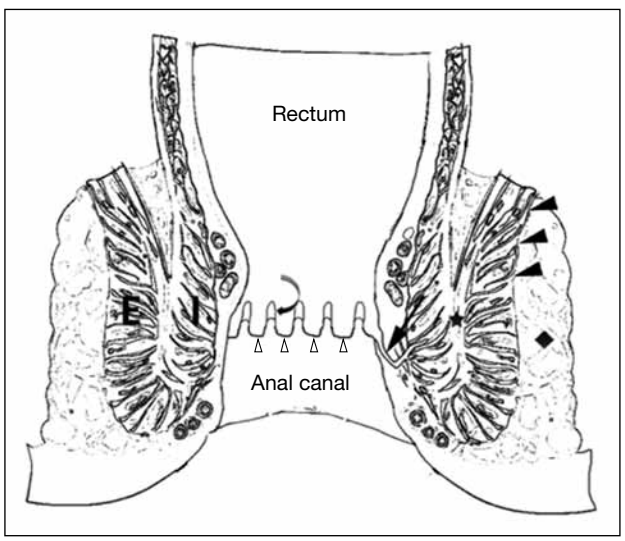

Figure 1. Drawing of the anal canal in the coronal plane shows the normal anatomy of the perianal region, with levator ani muscle (black arrowheads), column of Morgagni (curved arrow), dentate line (white arrowheads), anal crypt (black arrow), intersphincteric fat plane (★), ischioanal fossa (◆).
Abbreviations: E = external anal sphincter; I = internal anal sphincter.

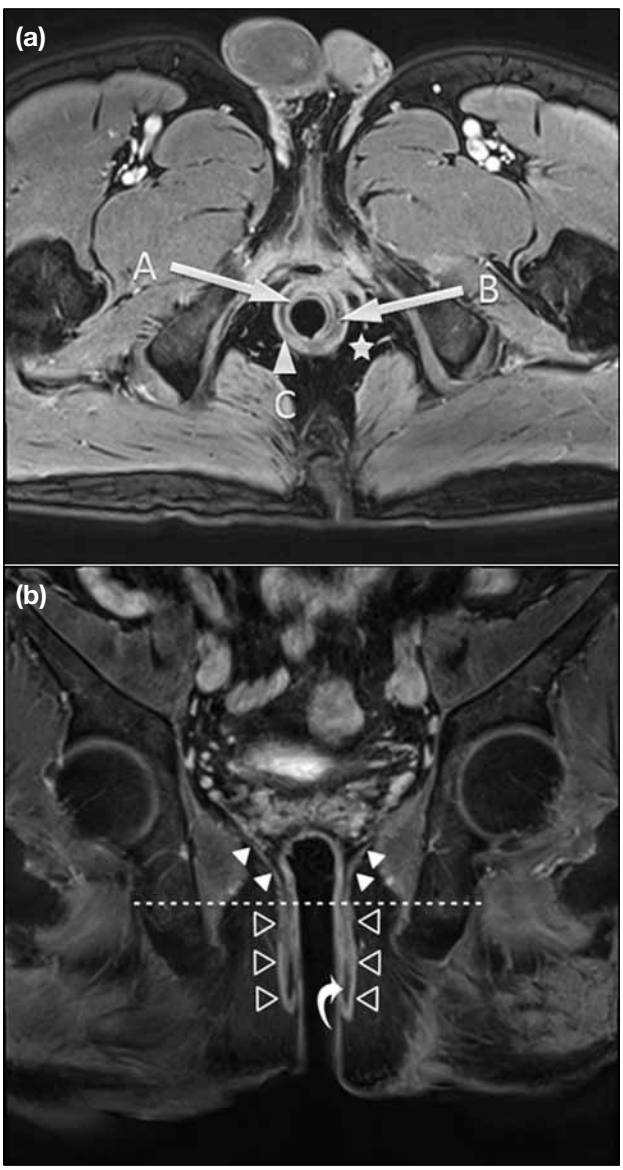

Figure 2. Enhanced T1-weighted magnetic resonance images with fat suppression. (a) Axial and (b) coronal images show the normal anatomy of the perianal region. The following features are shown: (a) internal sphincter (A), intersphincteric fat plane (B), external sphincter (C), ischioanal fossa (★); and in (b) levator ani muscle (solid arrowheads), external anal sphincter (hollow arrowheads), internal anal sphincter (curved arrow).

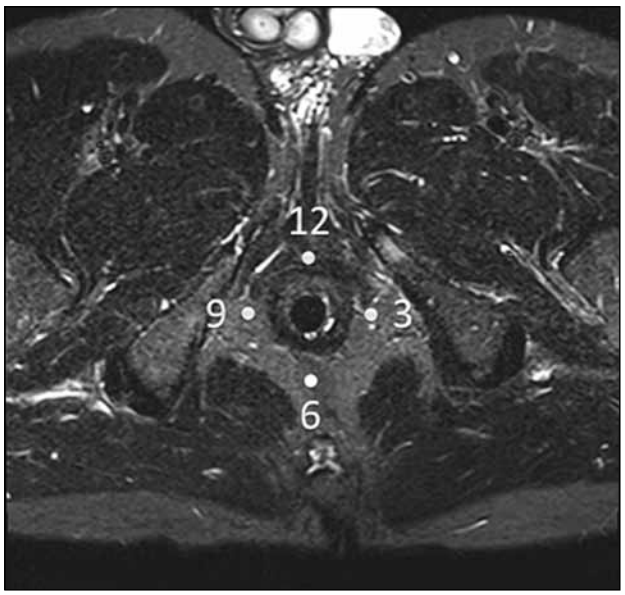

Figure 3. An axial T2-weighted magnetic resonance image with fat saturation shows the anal clock. The 12 o'clock position refers to the anterior midline, the 6 o'clock position refers to the intergluteal cleft, and the 3 o'clock and 9 o'clock positions refer to the left and right lateral aspects of the anal canal.

anterior perineum and at 6 o'clock is the intergluteal cleft; the 3 o'clock and 9 o'clock positions refer to the left and right lateral aspects of the anal canal, respectively. Using a common language allows better communication between radiologists and surgeons, which is equally important to correct detection and interpretation of MRI scans. Description of openings in terms of quadrants is not preferred.

PATHOPHYSIOLOGY

Almost 90% of perianal abscesses and fistulae follow the cryptoglandular theory, which describes suppuration of the anal glands as the origin of anorectal infections.[4] The anal glands are most concentrated in the posterior midline. They empty into the crypts of Morgagni at the level of the dentate line, and penetrate into the surrounding anal sphincters to a variable depth, with the majority not deeper than the intersphincteric plane. Infection of one of these anal glands can give rise to an abscess and, in the chronic phase, a fistula. Only about 10% of perianal sepsis arises from a non-cryptoglandular source, including Crohn's disease, tuberculosis, malignancy, trauma, and radiation therapy.

Goodsall's rule describes fistulae with an external opening in relation to the anterior half of the anus as tending to be of the direct type. Fistulae with an external opening or openings in relation to the posterior half of the anus, which is much more common, usually connect to a solitary internal orifice at the posterior midline.[3]

PREOPERATIVE EVALUATION

MRI is highly accurate for depicting the primary as well as secondary fistula tracts, horseshoe extension, and internal opening. Endoscopic ultrasound (EUS) has also been shown to be successful in experienced hands.[5] It is operator dependent, however. Scars and defects may confuse sonographic interpretation and render delineation of a fistula tract difficult. Also, the field of view is much smaller than that of MRI, which makes it less preferable in assessing the lateral extension of the fistula tract into the ischioanal fossa and cranial extension above the levator ani. Examination under anaesthesia (EUA) is both diagnostic and therapeutic. The drawbacks, obviously, are the invasiveness of the procedure and the necessity for general anaesthesia. Thus, EUA is usually performed only when surgery is contemplated. MRI, EUS, and EUA all have similarly high accuracy in identifying fistula tracts; and the diagnostic accuracy approaches 100% when MRI is combined with EUA.[6]

THERAPY

Fistulotomy is considered the procedure of choice for a simple fistula, which is defined as a single, non-recurrent tract that crosses less than 30% to 50% of the external anal sphincter, not anterior in a female, and is present in patients with perfect continence and no history of Crohn's disease or pelvic radiation.[7] The recurrence rate ranges from 0% to 9% and post-procedure incontinence ranges from 0% to 17%. Fistulectomy is generally inferior to fistulotomy as it results in a similar recurrence rate, but higher functional derangement after operation. Complex fistula can be treated with seton placement and / or staged fistulotomy, endorectal advancement flap, or fibrin glue injection.[7] Other surgical options include fistula plug, ligation of intersphincteric fistula tract, and radiofrequency ablation.[8]

TECHNIQUE

Both 1.5-T and 3-T MRI systems can be used to obtain high-resolution images of the pelvis. The higher field strength of the 3T system allows higher signal-to-noise ratio, which can be translated into higher spatial resolution, shorter acquisition time, or both. The drawbacks are higher susceptibility artefact and field inhomogeneity. In our centre, we use a pelvic-

Table. Pelvic magnetic resonance imaging protocol for evaluation of fistula-in-ano.*

Sequences and slice orientation	No. of signal averages	FOV (mm)	Acquired matrix (phase x frequency)	Slice thickness (mm)	Gap (mm)	TR/TE	Flip angle	Bandwidth
Sagittal T2-trufi (localiser)	1	225 x 300	163 x 256	4	0	3.7/1.5	60	454
Coronal T2-stir	1	240 x 240	502 x 512	5	0.5	6220/73	180	160
Axial T1-tse	3	220 x 220	544 x 640	5	1	484/12	150	150
Axial T2-stir	1	220 x 220	436 x 512	5	1	3600/73	180	160
Sagittal T2-spc (optional)	2	250 x 250	514 x 640	1	0	1500/132	150	651
Axial T1-VIBE with fat suppression	2	250 x 250	486 x 512	2.5	0	5.3/2.5	10	300
Axial T1-VIBE with contrast and fat suppression	2	250 x 250	486 x 512	2.5	0	5.3/2.5	10	300
Axial T1-VIBE with contrast, fat suppression and subtraction	2	250 x 250	486 x 512	2.5	0	5.3/2.5	10	300
Coronal T1-VIBE with contrast and fat suppression	2	250 x 250	486 x 512	2.5	0	5.3/2.5	10	300

Abbreviations: FOV = field of view; spc = single slab 3D turbo spin echo (Siemens); stir = short tau inversion recovery; TR/TE = repetition time/echo time; trufi = true fast imaging with steady-state free precession; tse = turbo spin echo; VIBE = volumetric interpolated breath-hold examination.
* All parameters presented are designed for a 1.5-T scanner.

phased array coil instead of an endoanal coil, as it provides a larger field of view and is more acceptable to symptomatic patients with severe anal pain. It should be stressed that assessment of perianal fistulas should be made on true axial and true coronal images along the long axis of the anal canal. This can be achieved by performing a sagittal T2-weighted localiser sequence at the beginning to depict the extent and orientation of the anal canal. It follows that in the majority of patients, 45° tilted axial and 45° tilted coronal planes provide the optimal visualisation of the region. The pelvic diaphragm and entire perineum have to be included for adequate evaluation of secondary tracts and abscesses.

The pelvic MRI protocol for evaluation of a fistula-in-ano consists of a T1-weighted sequence without fat saturation to delineate pelvic anatomy (external and internal sphincters, intersphincteric space, and ischioanal fossae); T2-weighted imaging sequences with fat saturation to detect fluid-containing tracts, oedema, and abscess cavities; and unenhanced and enhanced three-dimensional (3D) T1-weighted sequence with fat suppression to assess the presence and degree of inflammation (Table). Subtraction image from unenhanced and enhanced 3D T1-weighted sequence is generated to increase the conspicuity of the active tract. A high spatial resolution 3D T2-weighted sequence can be added to better delineate the fistula tract if necessary, e.g. when the exact location of the internal opening cannot be identified by routine sequences.

FISTULA CLASSIFICATION

Initial classification of a fistula-in-ano was based on surgical anatomy described by Parks et al.[9] Morris et al[10] subsequently modified the classification system based on the radiologic anatomy in pelvic MRI, which is known as the St James's University Hospital Classification. Both classifications describe perianal fistulae according to their relationship with the anal sphincter complex, integrity of the external sphincter and cranial extension into pelvis. The latter also takes into account the presence of associated abscesses and secondary tracts, which are surgically important as they serve as septic foci and result in recurrence if not properly managed. The St James's University Hospital Classification divides perianal fistula into five grades (Figure 4).[10]

Grade 1: Simple Intersphincteric Fistula

Grade 1 fistula (Figure 5) arises from the anal canal, penetrates the internal anal sphincter, and descends through the intersphincteric plane to its cutaneous opening. The external anal sphincter remains intact, and there are no secondary tracts, associated abscess, or supralevator component.

Grade 2: Intersphincteric Fistula with Intersphincteric Abscess or Secondary Fistulous Tract

Grade 2 fistula (Figure 6) refers to a grade 1 fistula with an intersphincteric abscess or secondary tract. Similar

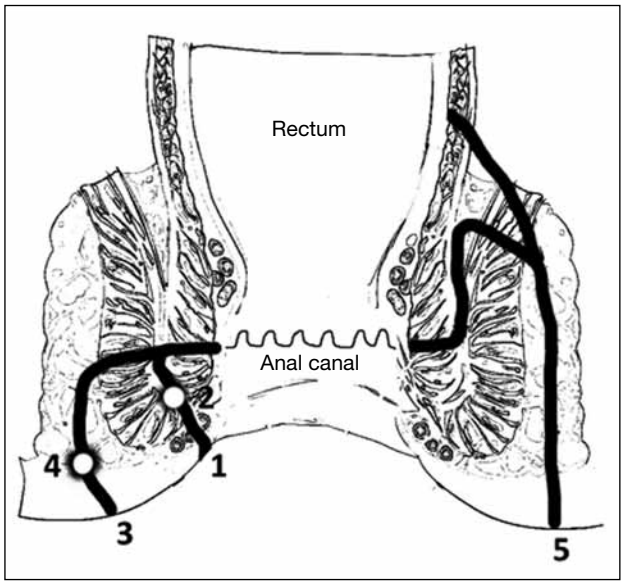

Figure 4. Drawing to demonstrate different grades of fistula-in-ano according to the St James's University Hospital Classification.[10] Grade 1 fistula is a simple intersphincteric fistula (1), grade 2 fistula is an intersphincteric fistula with secondary tract or intersphincteric abscess (2), grade 3 fistula is a simple trans-sphincteric fistula (3), grade 4 fistula is a trans-sphincteric fistula with secondary tract or associated abscess along the tract (4), and grade 5 fistula is signified by a supralevator component (5).

to a grade 1 fistula, a grade 2 fistula is confined by the intact external anal sphincter. The horseshoe extension is a subtype to describe a secondary tract that crosses the midline and surrounds both sides of the internal anal sphincter.

Grade 3: Simple Trans-sphincteric Fistula

Grade 3 fistula (Figure 7) arises from the anal canal, penetrates both the internal and external anal sphincters, and descends through the ischioanal fossa to open in the perianal skin. There are no secondary tracts, associated abscess, or supralevator component.

Grade 4: Trans-sphincteric Fistula with Abscess or Secondary Tract within the Ischioanal Fossa

Grade 4 fistula (Figures 8 and 9) is a grade 3 fistula complicated by abscess or secondary tracts. The pelvic diaphragm, however, should be intact.

Grade 5: Supralevator or Translevator Disease

Grade 5 fistula (Figure 10) is characterised by cranial

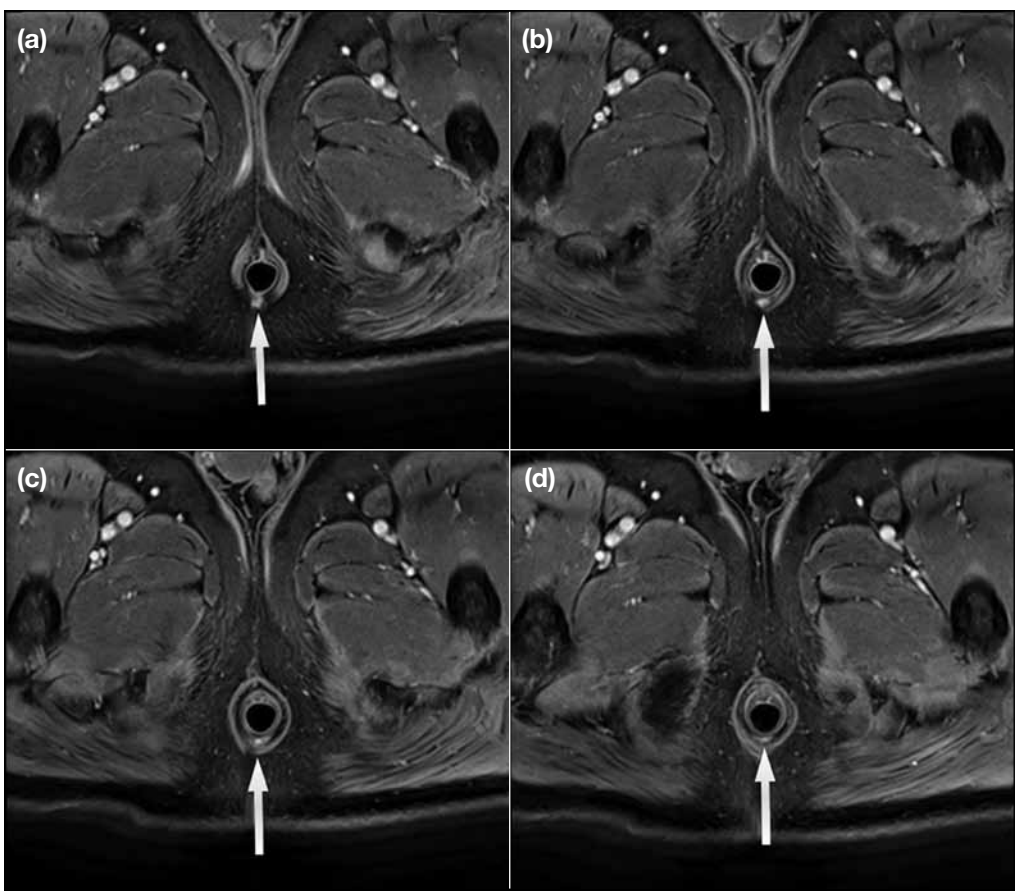

Figure 5. Axial enhanced T1-weighted magnetic resonance images with fat suppression demonstrates grade 1 simple intersphincteric fistula. (a-d) Serial images from caudal to cranial showing an active fistula tract (arrows) originating from the mid anal canal at 6 o'clock, penetrating the internal anal sphincter and descending through the intersphincteric fat plane to an external opening at 6 o'clock. The external anal sphincter and ischioanal fossae are intact. No secondary tract or intersphincteric abscess is seen.

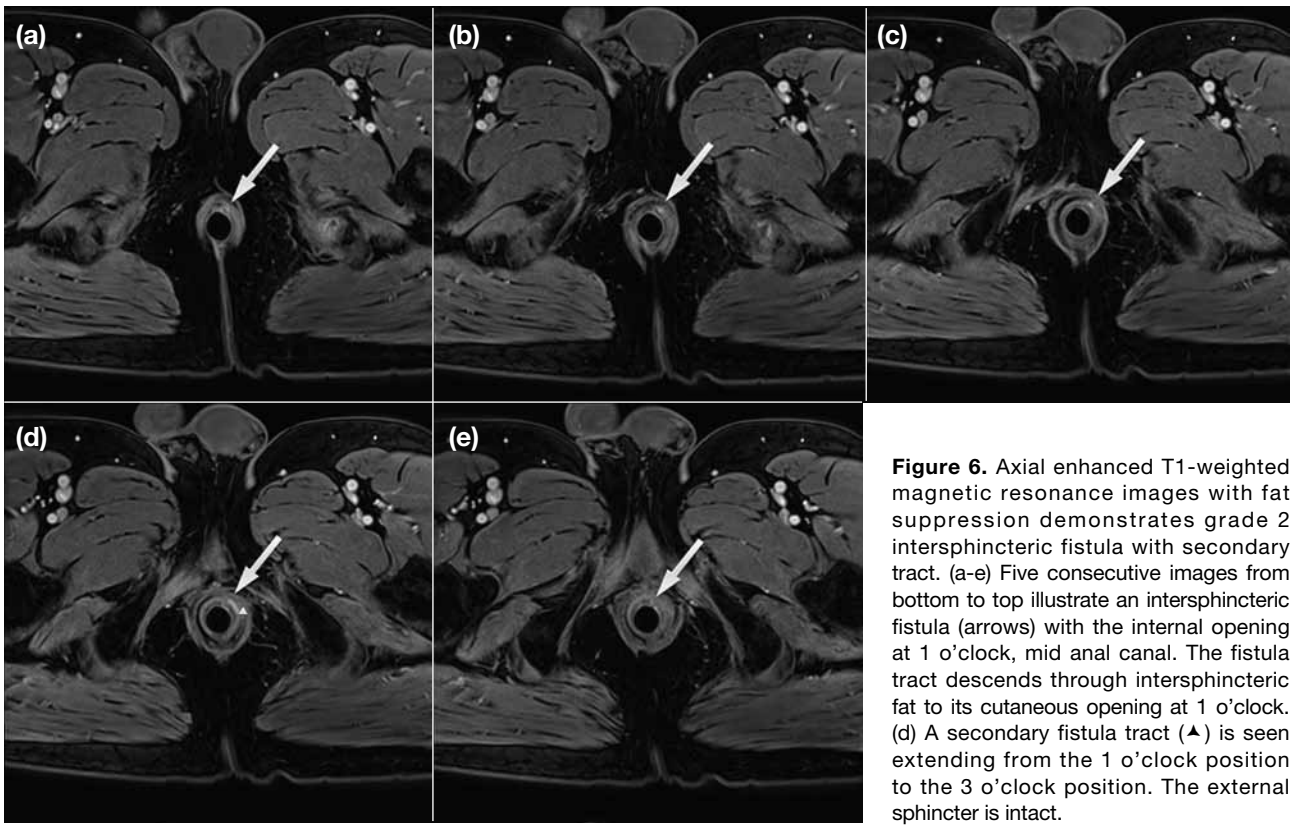

Figure 6. Axial enhanced T1-weighted magnetic resonance images with fat suppression demonstrates grade 2 intersphincteric fistula with secondary tract. (a-e) Five consecutive images from bottom to top illustrate an intersphincteric fistula (arrows) with the internal opening at 1 o'clock, mid anal canal. The fistula tract descends through intersphincteric fat to its cutaneous opening at 1 o'clock. (d) A secondary fistula tract (▲) is seen extending from the 1 o'clock position to the 3 o'clock position. The external sphincter is intact.

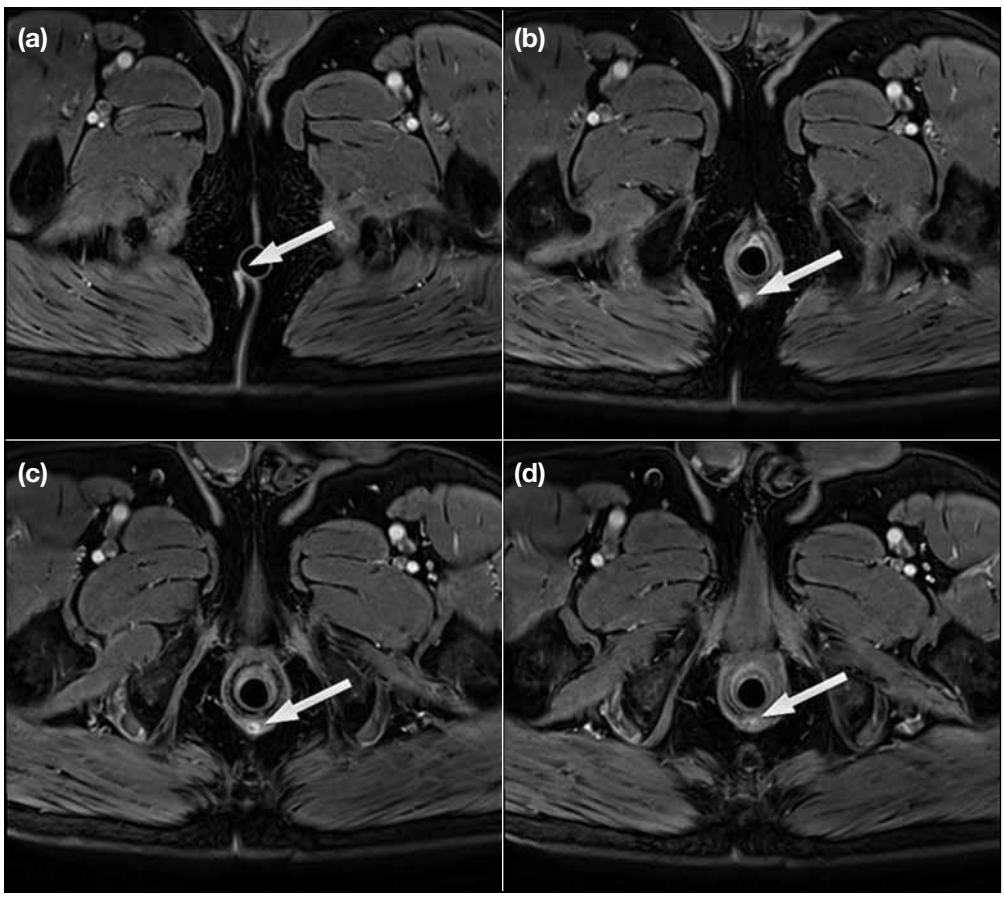

Figure 7. Magnetic resonance images of a grade 3 simple trans-sphincteric fistula. (a-d) Serial axial T1-weighted post-gadolinium images with fat suppression from bottom to top demonstrate an active fistula tract (arrows) with the internal opening at the 6 o'clock position of the mid anal canal. The tract pierces through both the internal and external anal sphincters to enter the right ischioanal fossa. The external opening is seen at 7 o'clock. No abscess or secondary tract is seen.

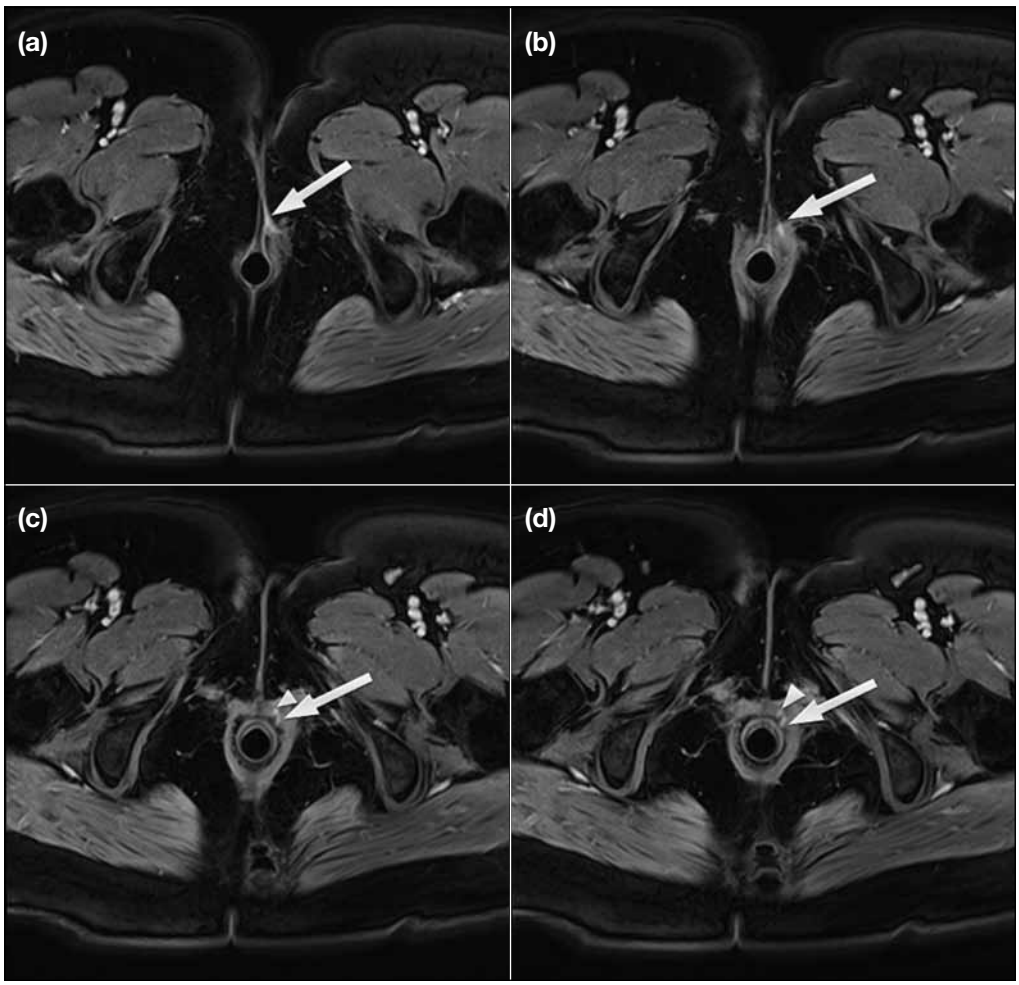

Figure 8. Axial enhanced T1-weighted magnetic resonance images show a grade 4 trans-sphincteric fistula with secondary tract. (a-d) Caudal to cranial images with fat saturation show the internal opening at the 2 o'clock position. The tract penetrates both the internal and external sphincters, and descends further in the left ischioanal fossa to end at the anterior midline. A secondary tract is seen at the 1 o'clock position (arrowheads in c and d). No abscess or involvement of levator ani is seen.

extension above the levator ani. A suprasphincteric fistula arises from the anal canal, penetrates the internal sphincter, extends upward through the intersphincteric plane to the supralevator space, and then passes through the levator ani as it descends through the ischioanal fossa to the perianal skin. An extrasphincteric fistula is caused by pelvic disease that extends caudally through the levator ani and ischioanal fossa to its cutaneous opening. Both internal and external anal sphincters are intact in such cases.

MRI INTERPRETATION

Fistula Detection and Tract Activity

Active fistula tract is hypointense relative to muscle in T1-weighted image, hyperintense in T2-weighted image with fat saturation, and shows contrast enhancement after gadolinium administration (Figure 11). The T2-weighted hyperintensity and contrast enhancement are thought to be due to granulation tissues with increased vascularity. During the healing process, loss of T2-weighted hyperintensity precedes lack of contrast enhancement. Eventually when the tracts become inactive, they manifest as T1-weighted hypointense, T2-weighted hypointense bands without contrast enhancement.

Fistula Classification

Fistula-in-ano should be classified according to the St James's University Hospital Classification,[10] as described above. Describing the fistula tract in relationship to the anal sphincter complex is preferred to simply give a grading, as the surgeons may not be using the same classification system as the radiologists. Appropriate examples to be written down in the report would be "intersphincteric fistula without secondary tract or abscess" or "trans-sphincteric fistula with an abscess in the left ischioanal fossa".

External and Internal Openings

External openings are usually obvious on physical

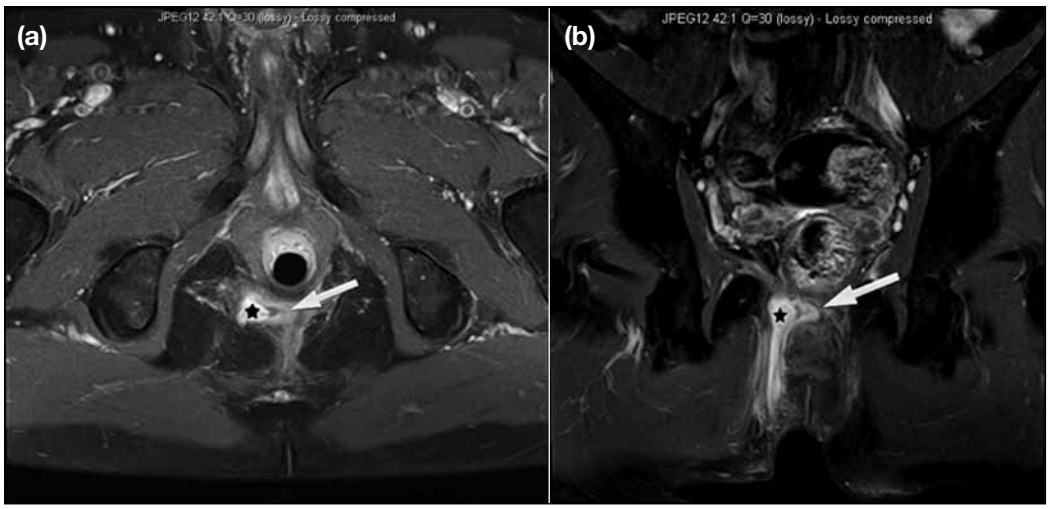

Figure 9. (a) Axial and (b) coronal enhanced T1-weighted magnetic resonance images with fat saturation illustrate a grade 4 trans-sphincteric fistula with associated ischioanal abscess. The rim-enhancing abscess at the right ischioanal fossa is shown by the arrow, ★ = fistula tract.

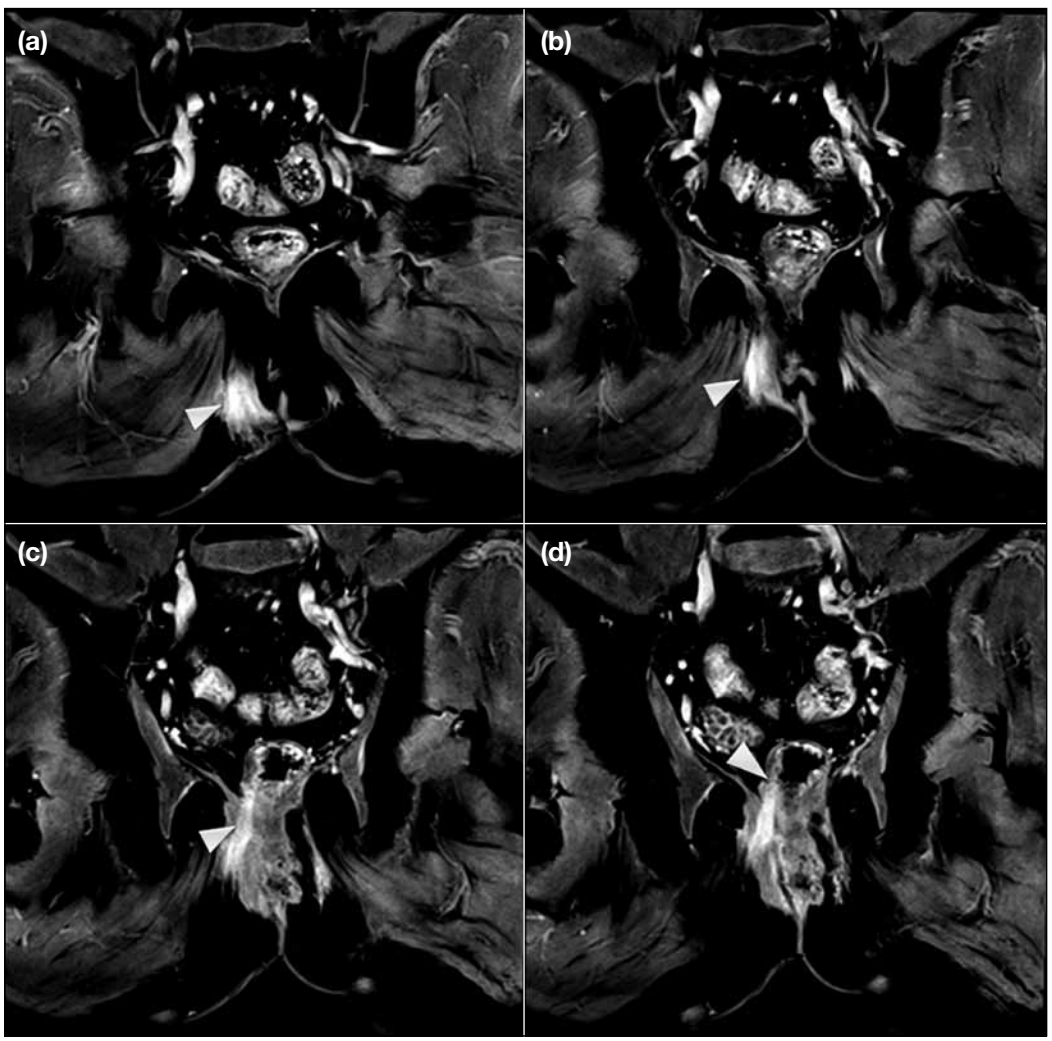

Figure 10. Coronal enhanced T1-weighted magnetic resonance images with fat suppression illustrate a grade 5 supralevator fistula (arrowheads). (a-d) Consecutive images from anterior to posterior show that the fistula tract begins at the lower rectum instead of the anal canal.

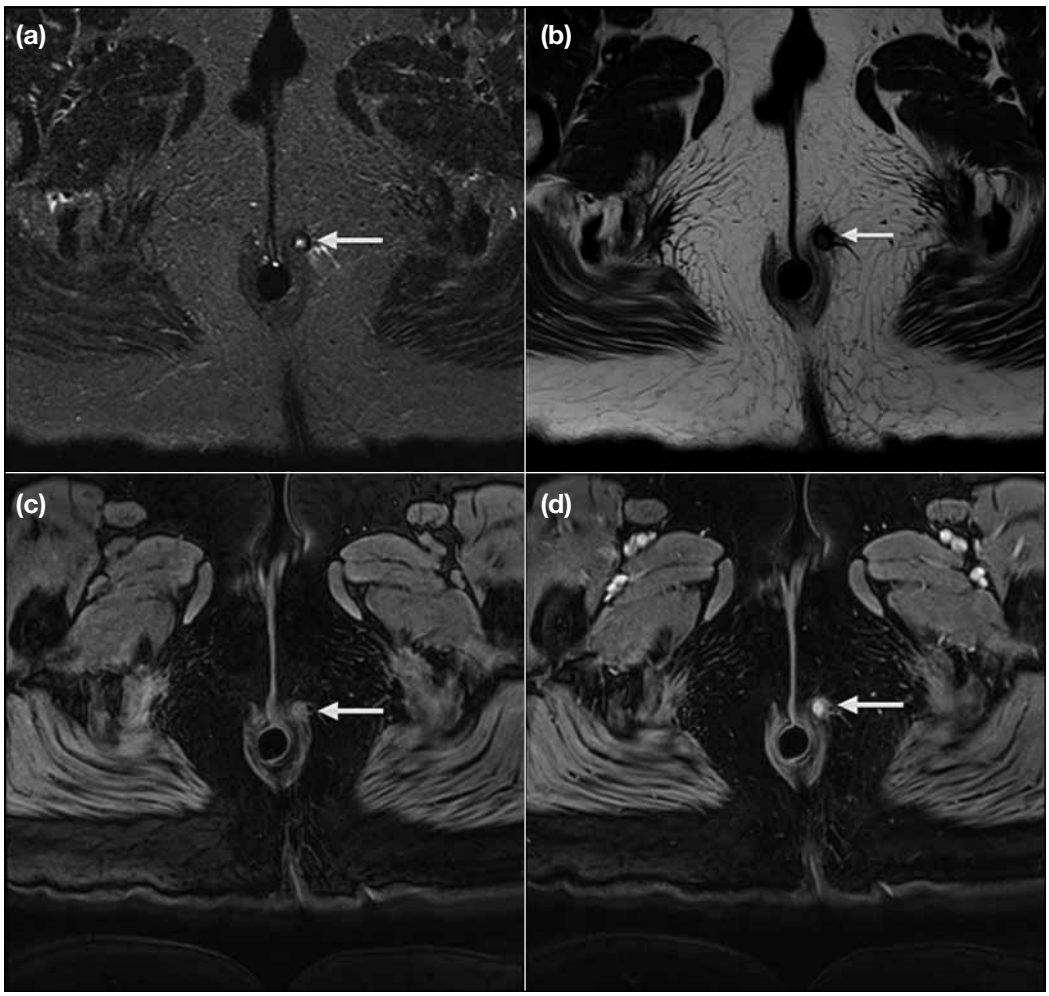

Figure 11. Magnetic resonance images show an active fistula tract (arrows). An active tract is (a) T2-weighted hyperintense, (b) T1-weighted hypointense with (c and d) contrast enhancement after administration of gadolinium.

examination. Detection of the internal opening is, however, more difficult, even after digital examination and proctoscopy by experienced hands. It is thus crucial for radiologists to identify the internal opening in MRI study. Both the external and internal openings should be described by referring to the anal clock. The level of the internal opening should also be reported, e.g. mid or upper third of the anal canal. It is particularly important in trans-sphincteric fistula, as the amount of external anal sphincter involved predicts post-procedure continence impairment. Seton placement and / or staged fistulotomy instead of simple fistulotomy should be performed if more than 50% of the external sphincter is involved by the tracts.[7]

Detection of Secondary Tracts and Abscesses

Secondary tracts have similar features to those of the primary tract, and their course should be reported relative to the anal sphincter complex and levator ani muscle. A horseshoe extension, if any, should also be reported. Perianal abscess can occur anywhere along the course of the fistula tract, and is typically T2-weighted hyperintense with rim enhancement after gadolinium administration. Any involvement of the levator ani should warrant scrutinisation of the pelvis to look for possible pelvic pathology, such as infection or malignancy.

Others

Post-treatment changes should also be noted. The most common change would be a seton, which manifests as a linear low signal intensity structure on both T1- and T2-weighted images.

CONCLUSION

Radiologists have an important role in the management

of fistula-in-ano. Detection of clinically undetectable fistula tracts and abscesses makes big differences to patients. We guide the surgical approach and help to achieve better outcomes, i.e. minimising recurrence and incontinence. Adequate knowledge of the relevant pelvic anatomy, pathophysiology, fistula classification, and their implications on the therapeutic options is key for proper MRI assessment of perianal fistula.

DECLARATION

Authors have no conflicts of interest or project support.

REFERENCES

1. Buchanan G, Halligan S, Williams A, Cohen CR, Tarroni D, Phillips RK, et al. Effect of MRI on clinical outcome of recurrent fistula-in-ano. Lancet. 2002;360:1661-2. cross ref
2. Buchanan GN, Halligan S, Williams AB, Cohen CR, Tarroni D, Phillips RK, et al. Magnetic resonance imaging for primary fistula in ano. Br J Surg. 2003;90:877-81. cross ref
3. Russell RC, Williams NS, Bulstrode CJ. Bailey & Love's short practice of surgery. 24th ed. London: Arnold Publishers; 2004.
4. Sainio P. Fistula-in-ano in a defined population. Incidence and epidemiological aspects. Ann Chir Gynaecol. 1984;73:219-24.
5. Orsoni P, Barthet M, Portier F, Panuel M, Desjeux A, Grimaud JC. Prospective comparison of endosonography, magnetic resonance imaging and surgical findings in anorectal fistula and abscess complicating Crohn's disease. Br J Surg. 1999;86:360-4. cross ref
6. Schwartz DA, Wiersema MJ, Dudiak KM, Fletcher JG, Clain JE, Tremaine WJ, et al. A comparison of endoscopic ultrasound, magnetic resonance imaging, and exam under anesthesia for evaluation of Crohn's perianal fistulas. Gastroenterology. 2001;121:1064-72. cross ref
7. Whiteford MH, Kilkenny J 3rd, Hyman N, Buie WD, Cohen J, Orsay C, et al. Practice parameters for the treatment of perianal abscess and fistula-in-ano (revised). Dis Colon Rectum. 2005;48:1337-42. cross ref
8. Shawki S, Wexner SD. Idiopathic fistula-in-ano. World J Gastroenterol. 2011;17:3277-85. cross ref
9. Parks AG, Gordon PH, Hardcastle JD. A classification of fistula-in-ano. Br J Surg. 1976;63:1-12. cross ref
10. Morris J, Spencer JA, Ambrose NS. MR imaging classification of perianal fistulas and its implications for patient management. Radiographics. 2000;20:623-35; discussion 635-7. cross ref