Hong Kong J Radiol. 2015;18:221-6 | DOI: 10.12809/hkjr1514263

CASE REPORT

Transarterial Treatment of Traumatic Carotid Cavernous Sinus Fistula with Carotid Artery Dissection and Ruptured Pseudoaneurysm Using Flow Diverter and Detachable Coils

JPK Chan[1], SMS Lo[1], CM Chan[1], WL Poon[1], YL Cheung[1], KW Shek[1], KW Tang[1], PH Wong[2]

Departments of [1]Radiology and Imaging and [2]Neurosurgery, Queen Elizabeth Hospital, Jordan, Hong Kong

ABSTRACT

Direct carotid cavernous sinus fistula is a common delayed complication of head trauma, particularly in patients with skull base fractures. When carotid cavernous sinus fistula occurs together with carotid artery dissection, it poses a big challenge regarding successful treatment. Endovascular treatment options include occlusion with detachable balloons, coils, and Pipeline flow diverters (Chestnut Medical Technologies, Menlo Park [CA], USA). Here we describe the successful management of a patient with dual pathology with traumatic carotid cavernous sinus fistula and internal carotid artery dissection with multiple pseudoaneurysms using flow diverters and detachable coils.

Key Words: *Aneurysm, false; Carotid-cavernous sinus fistula; Cerebral angiography; Treatment outcome*

中文摘要

使用分流器和彈簧圈經動脈治療外傷性頸動脈海綿竇瘻併發頸動脈剝離和假性動脈瘤破裂

陳沛君、羅尚銘、陳智明、潘偉麟、張毓靈、石家偉、鄧國穎、黃秉康

直接型頸動脈海綿竇瘻屬於顱外傷的常見遲發併發症，尤其好發於顱底骨折患者中。一旦頸動脈海綿竇瘻併發頸動脈剝離，對成功治療會構成很大挑戰。血管內治療方案包括使用可拆卸球囊、彈簧圈和管道分流器進行閉塞。本文描述一個使用分流器和彈簧圈成功治療外傷性頸動脈海綿竇瘻併發頸內動脈剝離和多個假性動脈瘤的病例。

INTRODUCTION

Carotid-cavernous sinus fistula (CCF) can be divided into four types according to the most commonly used classification by Barrow et al.[1] Direct CCF belongs to type A, formed by direct communication between the internal carotid artery (ICA) and the cavernous sinus. Type A CCFs are most commonly traumatic in nature.[2,3] These fistulas are of high flow, which seldom close spontaneously. Type A CCFs can be associated with symptoms such as pulsatile proptosis, conjunctival injection, and even intracerebral haemorrhage.[4] In view of these disabling symptoms, reliable and technically

Correspondence: *Dr Joyce PK Chan, Department of Radiology and Imaging, Queen Elizabeth Hospital, 30 Gascoigne Road, Jordan, Hong Kong.*
Email: hi_jpkchan@hotmail.com

Submitted: 27 Aug 2014; Accepted: 10 Nov 2014.

feasible treatment options are crucial to help these patients. When CCF occurs together with traumatic ICA dissection plus pseudoaneurysm formation, treatment is difficult and challenging. Here we share the successful endovascular treatment of this complicated pathology.

CASE REPORT

In July 2013, a 33-year-old man with good past health was admitted to Queen Elizabeth Hospital, Hong Kong, after a road traffic accident. He had been hit by a taxi and was found at the site unconscious with epistaxis and otorrhagia. Computed tomography (CT) of the head found an open depressed right temporal skull fracture with comminuted skull base fractures involving the right carotid canal (Figure 1). He had an acute right frontotemporoparietal subdural haemorrhage with mass effect and midline shift. Subarachnoid haemorrhage in the bilateral frontal regions and extensive cerebral oedema were also noted. Emergency craniotomy for clot evacuation and craniectomy for decompression were done. Initial postoperative CT of the brain showed an evacuated clot with diffuse subarachnoid haemorrhage and cerebral oedema. The patient stayed in the high dependency unit for further care.

At around 2 months after the injury, the patient developed a bulging craniectomy site. CT of the brain was repeated and showed a new right inferior frontal intracerebral haemorrhage with intraventricular extension complicated by obstructive hydrocephalus (Figure 2) and abnormal right cavernous sinus distension (Figure 3).

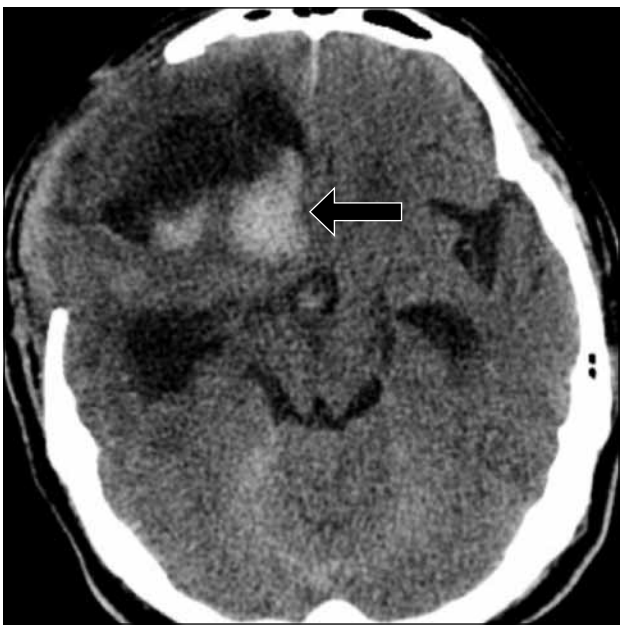

Figure 2. A computed tomography image at around 2 months after initial injury shows new intracerebral haemorrhage at the right inferior frontal lobe (arrow) with hydrocephalus.

Figure 1. A computed tomography image of the patient on admission shows extensive skull base fractures with involvement of the right carotid canal (arrow).

Figure 3. A selected computed tomography image shows abnormal distension of the right cavernous sinus (arrow).

Computed tomography angiography (CTA) showed abrupt change in calibre in the distal right ICA, suggestive of dissection. Multiple pseudoaneurysms were also seen arising from the right distal ICA, suggestive of pseudoaneurysm rupture giving rise to intracerebral haemorrhage. Abnormal early enhancement was noted in the right cavernous sinus, suggestive of underlying direct CCF formation (Figure 4). Patency in the distal right ICA, right middle cranial artery (MCA), anterior cranial artery, and anterior communicating artery were assured.

Endoventricular drainage (EVD) catheter insertion and digital subtraction angiography (DSA) embolisation were arranged the next day. Diagnostic DSA prior to endovascular treatment confirmed multiple pseudoaneurysms at the distal right ICA, with the largest being up to 1 cm with a wide neck in the ophthalmic segment. Several other subcentimetre pseudoaneurysms were noted in the cavernous segment. A CCF was seen with an opening at the medial aspect of the right cavernous ICA. Venous drainage of this CCF was to the retroclival and pterygoid venous plexuses (Figure 5). No venous drainage was noted into the superior ophthalmic veins. No abnormal venous reflux into the right sphenoparietal sinus or cortical veins was noted, excluding the possibility of haemorrhage from a haemorrhagic venous infarct due to venous hypertension. The DSA findings were in keeping with intracerebral haemorrhage from underlying pseudoaneurysm rupture.

Figure 4. A computed tomography angiography image shows abrupt change in calibre in the right internal carotid artery (black arrow), suggesting dissection. Pseudoaneurysm formation (curved black arrow) and early enhancement of the right cavernous sinus (white arrow) suggestive of direct carotid cavernous sinus fistula formation are also noted.

Figure 5. A digital subtraction angiography image shows pseudoaneurysms (black arrow) and direct right carotid cavernous sinus fistula (white arrow) that drained into the retroclival and pterygoid venous plexuses (curved black arrow).

Figure 6. A digital subtraction angiography image shows coil embolisation of the pseudoaneurysm.

A microguidewire was placed in the right MCA to protect the path along the right MCA for subsequent placement of the flow diverter. The right ophthalmic ICA pseudoaneurysm was then embolised using two Guglielmi detachable coils (GDCs) [Figure 6]. The CCF was subsequently entered and embolised using a total of eight GDCs (Figure 7).

After coiling, the right ICA was stented using the Pipeline Embolization Device (flow diverter; Chestnut Medical Technologies, Menlo Park [CA], USA), covering the neck of the pseudoaneurysm, direct CCF, and dissection (Figures 8 and 9). Post-procedural CTA confirmed complete occlusion of both the pseudoaneurysm and the CCF. Follow-up DSA performed 4 months later showed no evidence of residual or recurrent CCF or aneurysm.

After the endovascular treatment, no recurrence of bulging craniectomy site, intracerebral haemorrhage, or hydrocephalus were noted. The patient remained clinically stable and was discharged home. Although he has significant neurological deficit owing to the initial insult, he can sit up, obey simple commands, and communicate through gestures.

DISCUSSION

Traumatic CCF has been reported to have delayed presentations,[5,6] especially in non-communicable patients with impaired neurological state. Patients can present with ophthalmological or neurological symptoms, as in this patient, or with epileptic attacks.[6] Traumatic carotid dissection and pseudoaneurysm

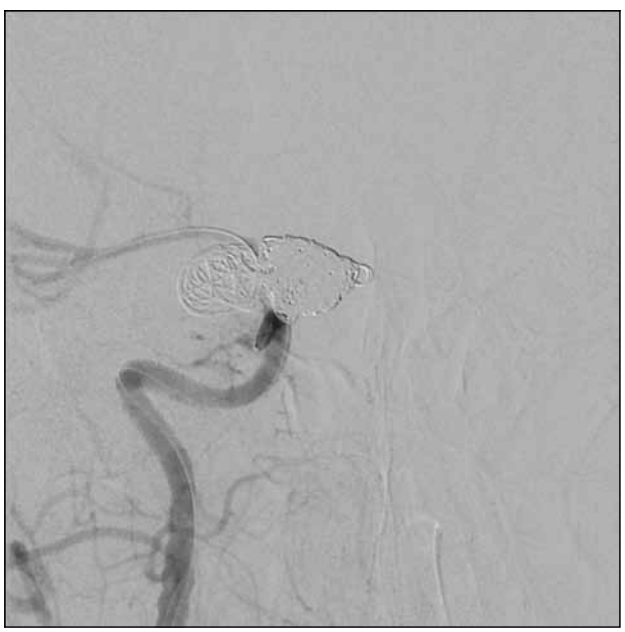

Figure 7. A digital subtraction angiography image shows coil occlusion of the carotid cavernous sinus fistula.

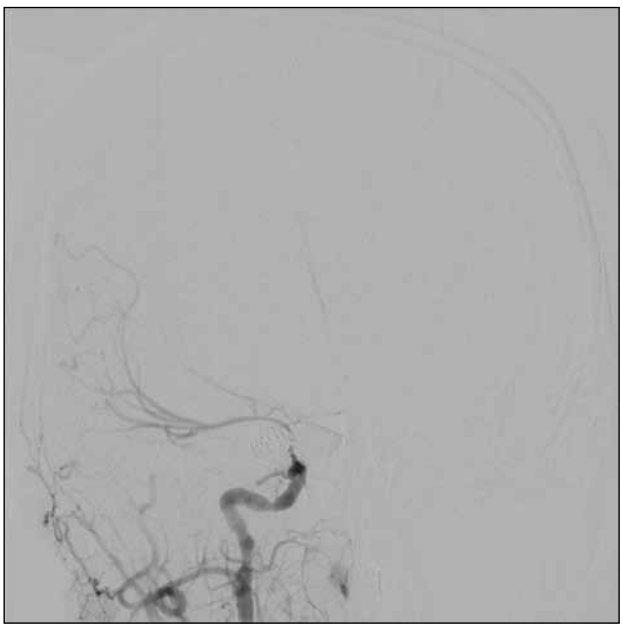

Figure 8. A digital subtraction angiography post-procedural angiogram image shows complete occlusion of the pseudoaneurysm and carotid cavernous sinus fistula after placement of the Pipeline Embolization Device.

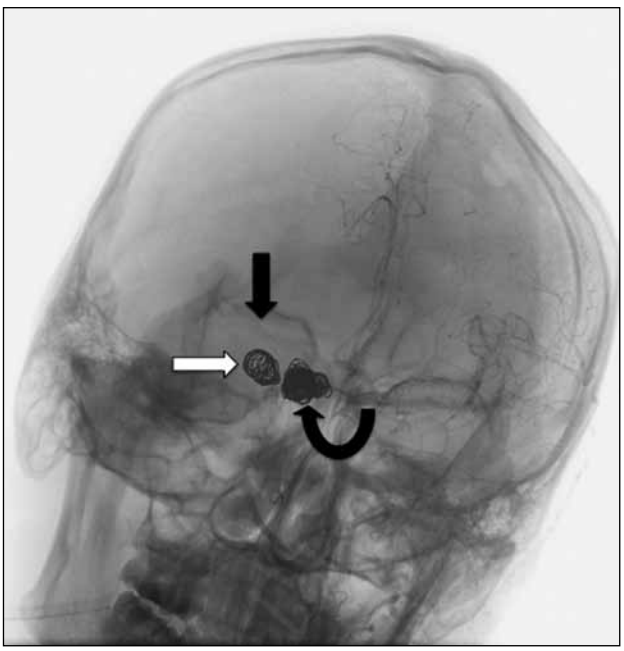

Figure 9. A unsubtracted angiogram image shows the Pipeline Embolization Device (black arrow), coil in the carotid cavernous sinus fistula (curved black arrow), and coil in the pseudoaneurysm (white arrow).

formation can present late, with presentation ranging from 2 weeks to 6 months after the initial trauma.[7] With this in mind, it is crucial to maintain vigilance against these two entities whenever there is a skull base fracture involving the carotid canal, and retain suspicion in high-risk cases, as in this patient with skull base fractures.

The endovascular treatment done for this patient is also highly challenging. Traumatic intracranial artery dissection with pseudoaneurysm formation is rare and difficult to treat. Together with the presence of CCF, the endovascular procedure is complex as it aims to treat all of these lesions at one time.

Treatment of traumatic pseudoaneurysms can be done using surgical or endovascular approaches. Surgical treatment options include craniotomy with clipping or entrapment of ICA. However, the presence of multiple pathologies along the diseased ICA made surgical treatment difficult. Therefore, endovascular treatment was preferred for this patient to preserve the patency of the ICA in view of the patient's young age.

Traditional endovascular treatment of CCF is done by using detachable balloons.[8-10] Detachable balloons have to be deployed within the cavernous sinus, which may be technically difficult as their placement is dependent on blood flow. Also, if the fistula contains more than one communication with the ICA, a single detachable balloon would not be able to treat the CCF. Detachable balloons are also associated with other technical difficulties such as rupture or deflation.[8,11] Detachable balloons have been unavailable in the USA since 2003 because of these problems, but have remained available for use in the rest of the world.

In this patient, we demonstrated that the combination of detachable coils with a flow diverter is a feasible and reliable treatment option for CCF with a low risk of recurrence. Flow diverters are low-porosity endovascular devices that are placed in the parent artery to treat intracerebral aneurysms and CCFs. These devices alter the flow dynamics at the interface between the parent artery and the aneurysm/CCF, reducing the flow rate in these pathologies thereby promoting thrombosis. After thrombosis, the inflammatory process with endothelial growth reconstructs the parent artery while preserving the flow in the perforators and side branches.

Low-porosity stents, as used in this patient, are most effective in reducing the flow rate in aneurysms, and are effective in inducing thrombosis. Low-porosity stents also allow epithelialisation along the stent after thrombosis, enabling reconstruction of the arterial wall. For high-porosity stents, coils have to be placed into the aneurysm sacs to occlude the flow. Also, epithelialisation along high-porosity stents for wall reconstruction is not possible. However, compared with high-porosity stents such as BX Sonic (Cordis Corp, Bridgewater [NJ], USA), low-porosity stents have a higher chance of causing hypoperfusion in the side branches, potentially causing ischaemic side-effects.

The Pipeline Embolization Device used in this patient is a low-porosity flow diverter of bimetallic composition: 75% cobalt chromium and 25% platinum tungsten. The stent has a 48-strand braided reconstruction in which the metallic strands are unfixed to each other. This property makes it flexible and mouldable, giving it the advantage of fitting into tortuous vessels. However, as the Pipeline Embolization Device is deployed into curved vessels, the pores between the braided metallic strands open up on the outer curve and narrow on the inner curve. These changes alter the porosity of the stent with relevance to the configuration of the vessel, which may have implications for its effectiveness in treating aneurysms.

An earlier report has shown that flow diverters are effective devices for treating traumatic CCF in a similar patient to the one in this report.[12] Flow diverters are also effective in treating pseudoaneurysms.[13] In this patient, using a flow diverter together with multiple coils, the complex ICA dissection, pseudoaneurysms, and CCF were treated with no recurrence. A flow diverter is especially useful to preserve ICA patency in patients with severe laceration of the ICA.[13,14] A flow diverter also has the advantage of covering multiple communication sites between the ICA and cavernous sinus, further reducing the risk of recurrence.

The literature regarding the use of flow diverters in treating traumatic ICA dissection is limited,[14] and we believe that this is one of the first few reports in our locality. It provides insights about the treatment of complex ICA injuries. Further experience and literature review are required to further refine the techniques.

There are other options available for treating intracerebral aneurysms, such as covered stent and balloon-assisted onyx injection. Covered stents are effective in occluding ruptured aneurysms. However,

as covered stents are not porous, they cannot be used in arteries with side branches and perforators, as in this patient. Also, most of the covered stents available are rigid, making navigation into tortuous vessels difficult. Balloon-assisted onyx injection can only be used in aneurysms with intact walls to contain the onyx. This was not feasible for this patient as he had traumatic pseudoaneurysms with no intact mural surface. With more experience and scientific evidence, the advantages of each of these devices can be better explored and their uses tailored to different pathologies.

Another treatment challenge for this patient was the requirement for heparinisation and antiplatelet agents to prepare for endovascular treatment immediately after EVD catheter insertion and in the presence of haemorrhage. EVD has been reported to be associated with haemorrhagic complications at a rate of 9.2% to 12.5% in some studies.[15,16] Patients with bleeding tendencies are at high risk. Evidence regarding the prescription of heparin immediately after EVD catheter insertion is limited. Hoh et al[16] reported that heparin was safe to use in preparation for cerebral aneurysm coiling, even within 24 hours after EVD catheter placement. Specific evidence regarding immediate heparinisation after EVD catheter placement for flow diverter insertion and CCF management is limited. This patient received 3000 units of intravenous heparin loading followed by 600 units per hour perfusion during the embolisation procedure. Double antiplatelet agents, 300 mg each of aspirin and clopidogrel, were given via a nasogastric tube as loading prior to the procedure. After the procedure, 6000 units of intravenous heparin were given every 12 hours for 1 day. Oral double antiplatelet agents were continued for 2 weeks after embolisation. After finishing the double antiplatelet course, the patient was given long-term oral enteric-coated aspirin 100 mg daily. This patient demonstrated that heparinisation and double antiplatelet agents are safe with no bleeding complications observed. Further research is required to reach consensus regarding the use of anti-coagulation and antiplatelet agents in these patients.

REFERENCES

1. Barrow DL, Spector RH, Braun IF, Landman JA, Tindall SC, Tindal GT. Classification and treatment of spontaneous carotid-cavernous sinus fistulas. J Neurosurg. 1985;62:248-56. cross ref
2. Gupta AK, Purkayastha S, Krishnamoorthy T, Bodhey NK, Kapilamoorthy TR, Kesavadas C, et al. Endovascular treatment of direct carotid cavernous fistulae: a pictorial review. Neuroradiology. 2006;48:831-9. cross ref
3. Halbach VV, Higashida RT, Hieshima GB, Hardin CW, Yang PJ. Transvenous embolization of direct carotid cavernous fistulas. AJNR Am J Neuroradiol. 1988;9:741-7.
4. d'Angelo VA, Monte V, Scialfa G, Fiumara E, Scotti G. Intracerebral venous hemorrhage in "high-risk" carotid-cavernous fistula. Surg Neurol. 1988;30:387-90. cross ref
5. Dubov WE, Bach JR. Delayed presentation of a carotid-cavernous sinus fistula in a patient with traumatic brain injury. Am J Phys Med Rehabil. 1991;70:178-80. cross ref
6. Begley A, Bell KE, Byrnes DP, McKinstry CS. Traumatic carotico-cavernous fistula presenting as epilepsy. Ulster Med J. 1993;62:101-4.
7. Pozzati E, Giuliani G, Poppi M, Faenza A. Blunt traumatic carotid dissection with delayed symptoms. Stroke. 1989;20:412-6. cross ref
8. Gemmete JJ, Ansari SA, Gandhi DM. Endovascular techniques for treatment of carotid-cavernous fistula. J Neuroophthalmol. 2009;29:62-71. cross ref
9. Goto K, Hieshima GB, Higashida RT, Halbach VV, Bentson JR, Mehringer CM, et al. Treatment of direct carotid cavernous sinus fistulae. Various therapeutic approaches and results in 148 cases. Acta Radiol Suppl. 1986;369:576-9.
10. Teng MM, Chang CY, Chiang JH, Lirng JF, Luo CB, Chen SS, et al. Double-balloon technique for embolization of carotid cavernous fistulas. AJNR Am J Neuroradiol. 2000;21:1753-6.
11. Lewis AI, Tomsick TA, Tew JM Jr. Management of 100 consecutive direct carotid-cavernous fistulas: result of treatment with detachable balloons. Neurosurgery. 1995;36:239-44; discussion 244-5. cross ref
12. Nadarajah M, Power M, Barry B, Wenderoth J. Treatment of a traumatic carotid-cavernous fistula by the sole use of a flow diverting stent. J Neurointerv Surg. 2012;4:e1. cross ref
13. Morón FE, Klucznik RP, Mawad ME, Strother CM. Endovascular treatment of high-flow carotid cavernous fistulas by stent-assisted coil placement. AJNR Am J Neuroradiol. 2005;26:1399-404.
14. Amenta PS, Starke RM, Jabbour PM, Tjoumakaris SI, Gonzalez LF, Rosenwasser RH, et al. Successful treatment of a traumatic carotid pseudoaneurysm with the Pipeline stent: Case report and review of the literature. Surg Neurol Int. 2012;3:160. cross ref
15. Joon H, Won IJ, Chung KC, Hae KP, Kyung JL, Hyoung KR. Hemorrhagic complications induced by external ventricular drainage catheters. Korean J Cerebrovasc Surg. 2011;13:256-62.
16. Hoh BL, Nogueira RG, Ledezma CJ, Pryor JC, Ogilvy CS. Safety of heparinization for cerebral aneurysm coiling soon after external ventriculostomy drain placement. Neurosurgery. 2005;57:845-9. cross ref