Hong Kong J Radiol. 2012;15:252-5

CASE REPORT

Stenosing Peroneal Tenosynovitis Associated with Hypertrophy of the Peroneal Tubercle

JWC Wai, KC Lai, MK Chan, SCH Chan

Department of Radiology and Imaging, Queen Elizabeth Hospital, Jordan, Hong Kong

ABSTRACT

Peroneal tenosynovitis in association with hypertrophy of the peroneal tubercle is part of the differential diagnosis of lateral foot and ankle pain. When the peroneal tubercle is enlarged, it can be a source of discomfort when wearing shoes, but it rarely causes tenosynovitis of the peroneal tendons. We report on a 63-year-old man who had stenosing tenosynovitis of peroneus tendon in association with hypertrophy of the peroneal tubercle. Illustrative features on ultrasonography and computed tomography will be demonstrated in this report.

Key Words: *Peroneal nerve; Tendons; Tomography, X-ray computed; Ultrasonography*

中文摘要

與跟骨腓肌腱骨突肥大增生相關的狹窄性肌腱炎

衛頴莊、黎國忠、陳文光、陳慈欽

與跟骨腓肌腱骨突肥大增生相關的肌腱炎是足外側及外踝疼痛鑑別診斷的其中一部份。跟骨腓肌腱骨突增大可引致病人穿鞋時的不適，但很少會導致狹窄性肌腱炎。本文報告一名63歲男性，他出現跟骨腓肌腱骨突肥大增生相關的狹窄性肌腱炎。本文將示例病症在超聲及電腦斷層影像上的特徵。

INTRODUCTION

Peroneal tubercles (peroneal trochlea, trochlear process) are located at the junction of the anterior and middle third of the lateral wall of the calcaneus.[1,2] The bony process is the base of a septum separating the peroneus longus and the peroneus brevis tendon sheaths, and it also fixes the pulley of these tendons. When the peroneal tubercle is enlarged, it can be a source of discomfort when wearing shoes, but it rarely causes tenosynovitis of the peroneal tendons. We report on a 63-year-old man with peroneal tenosynovitis due to enlarged peroneal tubercles.

CASE REPORT

A 63-year-old man presented in June 2010 with pain on the lateral aspects of both ankles for one year. The pain was more severe on the right side. He had no history of trauma to the affected regions. On physical examination, there were bony prominences at both peroneal trochleae, and swelling and tenderness along the peroneus longus tendons. His ankle and hindfoot range of motion were normal and symmetric bilaterally. There were no signs of flat foot, cavus foot, forefoot adductus, or valgus foot. Routine ankle anteroposterior and calcaneal radiography showed a prominence at the lateral sides of

Correspondence: *Dr Janet WC Wai, Room 115, Block K, Department of Radiology and Imaging, Queen Elizabeth Hospital, 30 Gascoigne Road, Kowloon, Hong Kong.*
Tel: (852) 2958 8888 ; Fax: (852) 2958 5653 ; Email: wwc053@ha.org.hk

Submitted: 3 Jan 2012; Accepted: 23 Feb 2012.

the calcanei bilaterally. Ultrasonography demonstrated bilateral enlarged peroneal tubercles contacting thickened peroneus tendons. The enlargement of the tendon diameters with increased hypoechoic spaces between the echogenic fibrils suggested tendinosis. Anechoic to hypoechoic fluid was found around in the tendon sheaths bilaterally. These results confirmed tenosynovitis (Figures 1 to 5). Computed tomography (CT) of the feet confirmed the presence of enlarged peroneal tubercles arising from the bilateral lateral calcaneal walls, which were more apparent on the right side. On volume-rendered images, thickening of the peroneus longus tendons were found distal and inferior to the peroneal tubercles (Figures 6 to 8). These imaging features confirmed bilateral peroneal tenosynovitis with hypertrophy of the peroneal tubercles. Options of conservative treatment versus surgical intervention were discussed. The patient's symptoms improved with anti-inflammatory drugs, so no operation was performed.

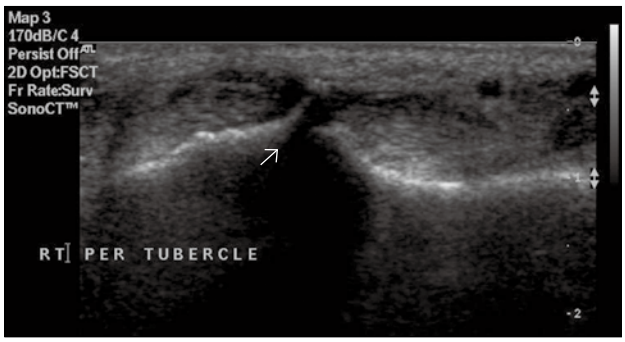

Figure 1. A longitudinal ultrasonogram shows a hypertrophic right peroneal tubercle (arrow).

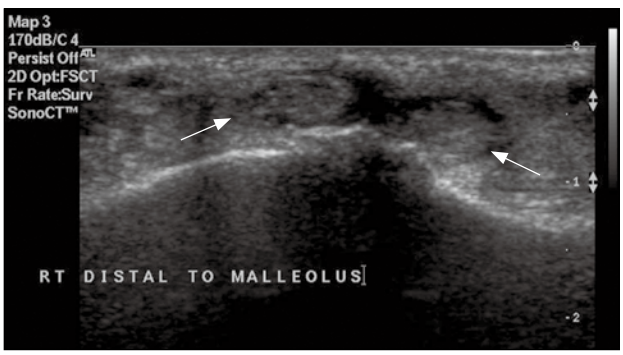

Figure 2. A transverse ultrasonogram of the lateral calcaneus shows thickened right peroneus tendons (arrows) with surrounding anechoic effusion.

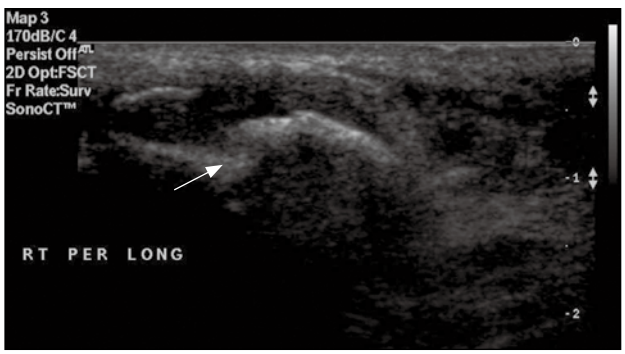

Figure 3. A longitudinal ultrasonogram shows calcified changes in the right peroneus longus tendon (arrow).

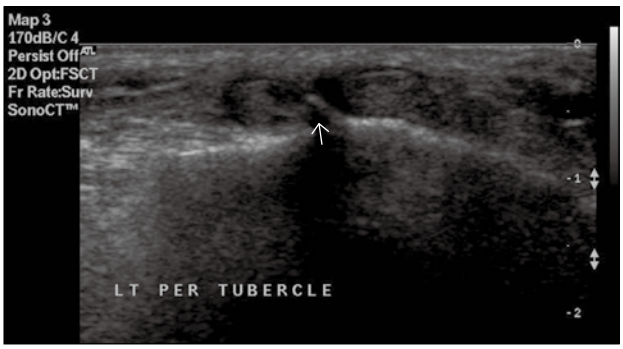

Figure 4. A longitudinal ultrasonogram shows a hypertrophic left peroneal tubercle (arrow), which is less severe than the right side.

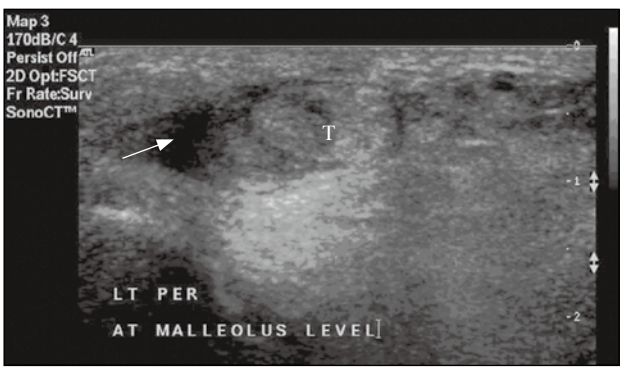

Figure 5. An ultrasonogram shows a thickened left peroneus tendon (T) with surrounding effusion (arrow).

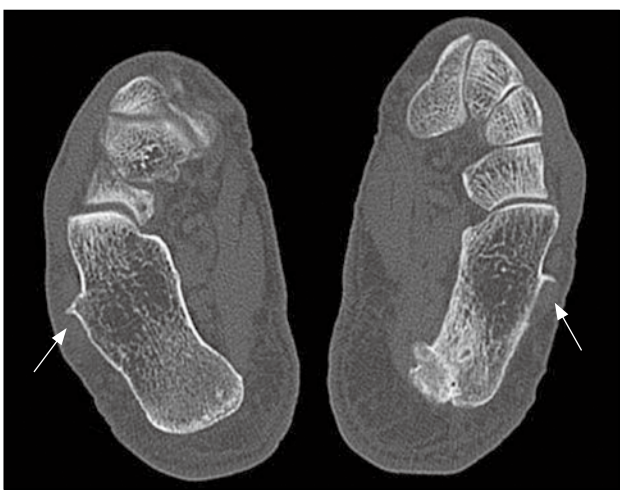

Figure 6. A computed tomography axial image shows hypertrophic bilateral peroneal tubercles (arrows).

Figure 7. Reformatted 3-dimensional computed tomography images of hypertrophic bilateral peroneal tubercles (arrows). Calcified changes along the right peroneus longus tendon can also be seen inferior to the right peroneal tubercle.

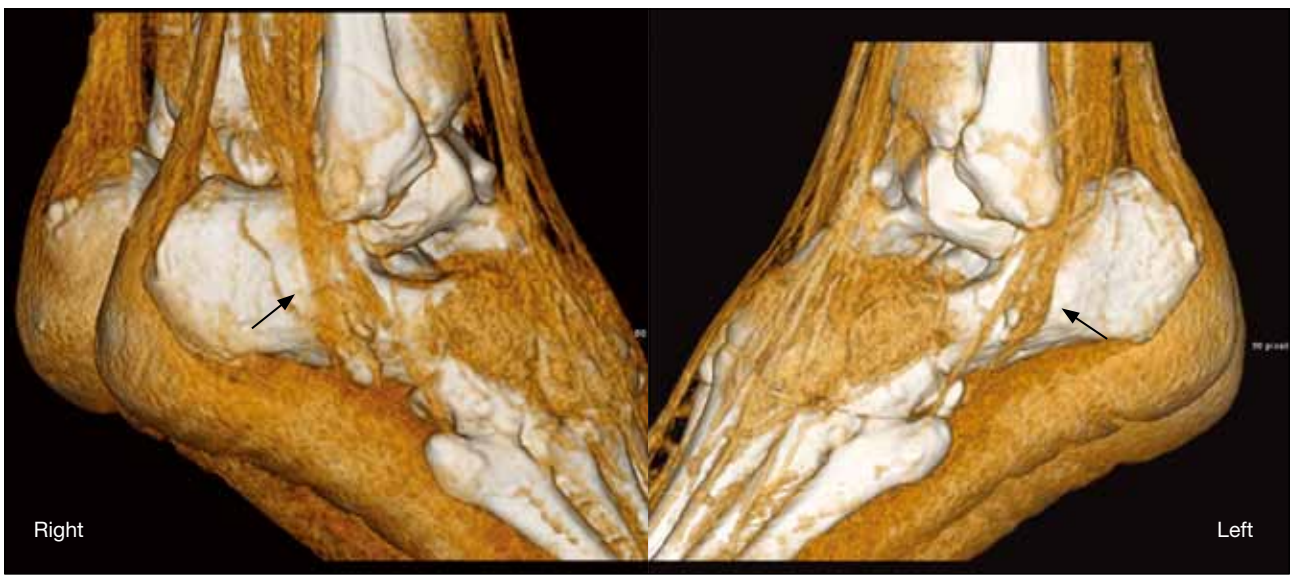

Figure 8. Reformatted 3-dimensional computed tomography images with soft tissue preference showing hypertrophic bilateral peroneal tubercles with thickened peroneus longus and brevis tendons (arrows).

DISCUSSION

Prominence of the peroneal tubercle was originally described by Burman.[3] The shape of the peroneal tubercle is variable and may be prominent in up to 30% of calcanei.[4] The peroneal tubercle is a bulge of variable size at the lateral side of the calcaneus with an incidence ranging between 36% and 97%.[2] Most of the patients reported in the literature had noted the existence of a bony prominence under the lateral malleolus for a long time before symptoms occurred. Some of these enlargements of the peroneal tubercle might be acquired by trauma, altered weight bearing, and / or inflammatory changes related to peroneus longus tendon spasms. However, most of these enlargements are principally believed to be congenital.[5]

Peroneal tenosynovitis associated with a hypertrophic peroneal tubercle should be included in the differential diagnosis of lateral foot and ankle pain.[6] In the presence of a hypertrophic peroneal tubercle, the inferior peroneal retinaculum is often thickened and the peroneal tendons are trapped by the rigid sheet of connective tissue. Stenosis may occur at the retromalleolar sulcus, at the peroneal tubercle, or under the cuboid.[7]

Hypertrophy of the tubercle increases the lateral position of the tubercle which, at the same time, increases tension of the tendon. The portion of the peroneus longus tendon that is located between the fixed bony points of the tubercle and cuboid may be stretched in the presence of an enlarged peroneal tubercle, and may tear on sudden or repeated inversion movements.[3] An enlarged peroneal tubercle is most commonly associated with tenosynovitis and rupture of the peroneus longus tendon.[2,7] Owing to the long excursion and changing direction of the tendon, the peroneus longus tendon is more easily affected by the stenotic canal than is the peroneus brevis tendon.

Ultrasonography

Ultrasonography may have a useful role in evaluation of both the spur and associated tendon abnormality. Ultrasonographically, tendinosis is seen as enlargement of the tendon diameter with increased hypoechoic spaces between the echogenic fibrils. Anechoic or hypoechoic fluid in the tendon sheath is suggestive of tenosynovitis, with or without tendinosis.[8] Small amounts of tendon sheath fluid can be normal. For example, in the case of the flexor hallucis longus, tendon sheath fluid can be associated with communication with tibiotalar joint fluid.[9] Tendon tears are shown as disruptions of the uniformly parallel echogenic fibrils by hypoechoic or anechoic clefts or gaps in the tendons.

Computed Tomography

Imaging of tendons has been the domain of magnetic resonance imaging and ultrasonography. The effectiveness of both techniques has been well validated.[10] However, ultrasonography is limited in that it is not widely accepted by orthopaedic surgeons due to the lack of overall impression for surgical planning. Ultrasonography cannot be used for some patients because of surgical wounds in the site of interest. Multidetector CT has had a considerable impact on musculoskeletal imaging, especially for trauma. Post-processing on CT data sets can be applied in commercially available workstations to quantify differences in attenuation values among bone, tendon, and muscle to display 3-dimensional volume-rendered images of normal tendons.[11]

Management

Initial treatment of peroneal tenosynovitis includes immobilisation and anti-inflammatory medication. The use of local anaesthetic injection or peritendinous steroid injection has not shown long-term benefits. Surgical decompression with excision of the hypertrophic peroneal tubercle and repair of the degenerated peroneus tendon can be an option resulting in complete resolution of a patient's chronic symptoms.

Peroneal tenosynovitis in association with hypertrophy of the peroneal tubercle is part of the differential diagnosis of lateral foot and ankle pain. Familiarity with radiological features in various modalities can enable confident diagnosis of this rare disease entity.

REFERENCES

1. Bisceglia CF, Sirota AD, Dull DD. An unusual case of hypertrophied peroneal tubercles. J Am Podiatry Assoc. 1983;73:481-2.
2. Hyer CF, Dawson JM, Philbin TM, Berlet GC, Lee TH. The peroneal tubercle: description, classification, and relevance to peroneus longus tendon pathology. Foot Ankle Int. 2005;26:947-50.
3. Burman M. Subcutaneous tear of the tendon of the peroneus longus; its relation to the giant peroneal tubercle. AMA Arch Surg. 1956;73:216-9.
4. Trevino S, Gould N, Korson R. Surgical treatment of stenosing tenosynovitis at the ankle. Foot Ankle. 1981;2:37-45.
5. Bruce WD, Christofersen MR, Phillips DL. Stenosing tenosynovitis and impingement of the peroneal tendons associated with hypertrophy of peroneal tubercle. Foot Ankle Int. 1999;20:464-7.
6. Ochoa LM, Banerjee R. Recurrent hypertrophic peroneal tubercle associated with peroneus brevis tendon tear. J Foot Ankle Surg. 2007;46:403-8.
7. Taki K, Yamazaki S, Majima T, Ohura H, Minami A. Bilateral stenosing tenosynovitis of the peroneus longus tendon associated with hypertrophied peroneal tubercle in a junior soccer player: a case report. Foot Ankle Int. 2007;28:129-32.
8. Fessell DP, Vanderschueren GV, Jacobson JA, Ceulemans RY, Prasad A, Craig JG, et al. US of the ankle: technique, anatomy, and diagnosis of pathologic conditions. Radiographics. 1998;18:325-40.
9. Rawool NM, Nazarian LN. Ultrasound of the ankle and foot. Semin Ultrasound CT MR. 2000;21:275-84.
10. Lin J, Fessell DP, Jacobson JA, Weadock WJ, Hayes CW. An illustrated tutorial of musculoskeletal sonography: part 3, lower extremity. AJR Am J Roentgenol. 2000;175:1313-21.
11. Pelc JS, Beaulieu CF. Volume rendering of tendon-bone relationships using unenhanced CT. AJR Am J Roentgenol. 2001;176:973-7.