

---

## CASE REPORT

---

# Immunoglobulin G4-related Sclerosing Disease of the Breast

KY Kwok, HS Fung, LF Chiu, KM Chu, JCW Siu, KH Lai, TS To, SCH Chan

Department of Radiology and Imaging, Queen Elizabeth Hospital, 30 Gascoigne Road, Hong Kong

### ABSTRACT

*Immunoglobulin G4-related sclerosing disease is a recently advocated disease entity. Though initially described as giving rise to autoimmune pancreatitis, this condition was subsequently found to involve extra-pancreatic tissues as well. In this report, we present a case of extra-pancreatic immunoglobulin G4-related sclerosing disease of the breast, with relevant imaging features on mammography, ultrasound, and magnetic resonance imaging.*

*Key Words: Immunoglobulin G; Magnetic resonance imaging; Mammography; Sclerosis; Ultrasonography*

## 中文摘要

### 免疫球蛋白G4相關性乳腺硬化性疾病

郭啟欣、馮漢盛、趙朗峰、朱嘉敏、蕭志偉、黎國鴻、杜德信、陳慈欽

免疫球蛋白G4相關性硬化性疾病是近年來熱門研究的一種疾病。雖然這病起初被認為導致自身免疫性胰腺炎，後來證實其亦涉及胰腺外的組織。本文報告一宗免疫球蛋白G4相關性硬化性疾病牽涉胰腺外組織乳腺的病例，並討論有關的乳腺X光攝影、超聲波及磁力共振的影像學特徵。

### INTRODUCTION

Immunoglobulin (Ig) G4-related sclerosing disease is a recently advocated disease entity,<sup>1</sup> which can be regarded as a systemic condition. It was initially described as an autoimmune pancreatitis<sup>2</sup> and majority of the cases show pancreatic involvement.<sup>3</sup> Nevertheless, it can manifest as extra-pancreatic disease without pancreatic involvement. The emphasis of this case report is on imaging features of this disease entity on mammography, ultrasound, and magnetic resonance imaging (MRI) of the breasts, there being no pancreatic involvement in our patient.

### CASE REPORT

A 47-year-old woman with good past health presented with a right breast mass for 2 months in 2008. There was

no family history of breast cancer. Physical examination revealed a 4-cm mobile mass at the 9 o'clock position. No axillary lymphadenopathy was detected.

Mammography showed that both breasts were intermediate in density, and multiple equal-density masses with obscured margins were also noted (Figure 1). There was no associated suspicious calcification or architectural distortion.

Ultrasound showed multiple masses of various sizes with similar features in both breasts. The lesions were hypoechoic with lobulated margins, and were wider than tall and there was no posterior shadowing or suggestion of abnormal vascularity. The largest lesion was at the 9 o'clock position of right breast (R9H)

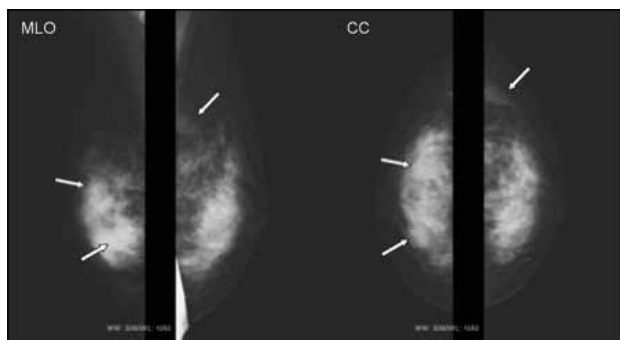
---

*Correspondence: Dr KY Kwok, Department of Radiology and Imaging, Queen Elizabeth Hospital, 30 Gascoigne Road, Hong Kong. Tel: (852) 2958 2699; Email: kwok\_kai\_yan@hotmail.com*

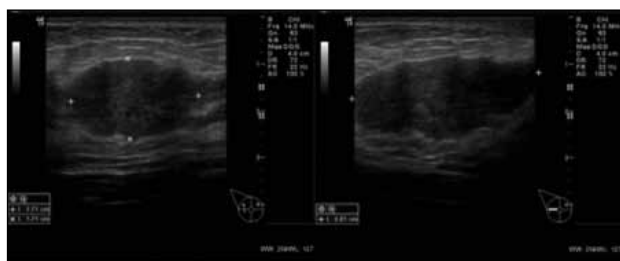Submitted: 24 May 2010; Accepted: 30 Jun 2010.

position (Figure 2) and corresponded to the palpable index lesion. Ultrasound-guided core biopsy of the palpable mass at the R9H position of the right breast was performed. Another lesion in left breast at the L2H position was also biopsied under ultrasound guidance. Pathology reports of both lesions revealed similar histological features, showing strips of breast tissue with sclerosis and a patchy dense lymphoid infiltrate with many IgG4+ plasma cells. It was suggested that the overall features were those of a reactive lymphoid infiltrate associated with fibrosis and infiltration by IgG4+ plasma cells.

MRI of both breasts was performed using a 1.5-Tesla Siemens MANETUM Avanto machine with a dedicated double breast coil. The patient was scanned in a prone position. The imaging protocol included T2-TSE-FS-TRA, T1-TSE-TRA, f13d-dynamic-tra post-contrast scans with subtraction and maximum intensity projection, epi-slab-t2\*first-pass perfusion-tra-5mm post-contrast images. In both breasts there were 9 masses in total. The largest one in the right breast was at the R9H position, corresponding to the biopsied palpable lesion and the largest one in left breast was in the L2H position corresponding to the other biopsied



**Figure 1.** Mammogram of both breasts with medial lateral oblique (MLO) and cranial-caudal (CC) views. They show multiple equal-density masses (arrows) with obscured margins.



**Figure 2.** Ultrasound images of the palpable index lesion at the 9 o'clock position of right breast. The lesion measured 2.7 x 1.7 x 4.0 cm. It was hypoechoic with lobulated margin. There was no posterior shadowing or abnormal vascularity. All the other lesions in both breasts showed similar features.

lesion. All of the masses showed similar features (Figure 3a to 3c). They were oval-shaped with lobulated margins. They were T1 isointense, T2 heterogenous with hyperintense components and showed homogenous internal enhancement. The time-intensity enhancement curve revealed a slow initial rise and absence of washout (type I curve) [Figure 3d].

The palpable lesion at the R9H position and another mass at the R3H position of the right breast were subsequently excised. The surgical specimens revealed pathological features identical to the biopsy results. Thus, the final diagnosis of IgG4-related sclerosing disease of breast was confirmed.

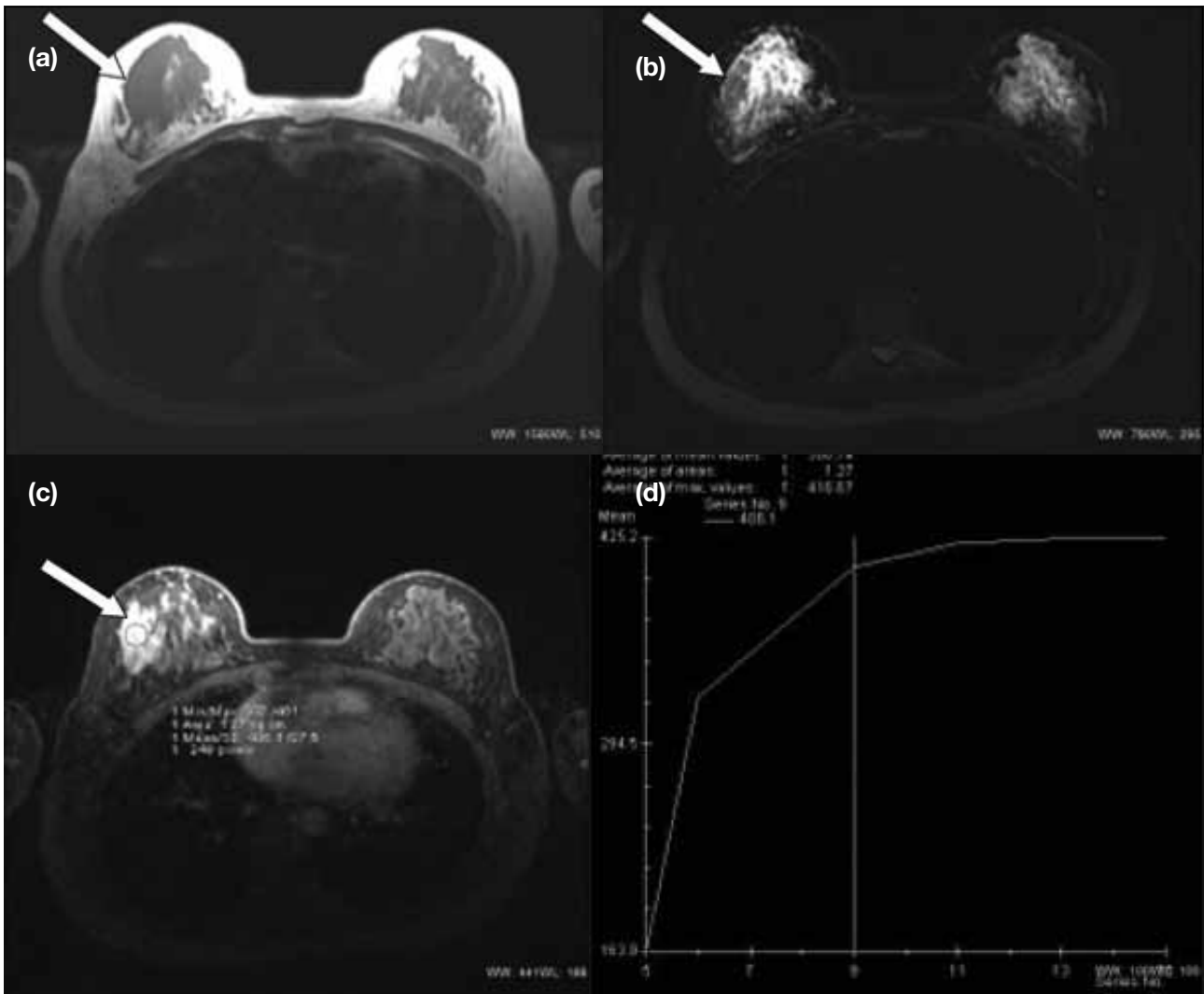
Subsequent blood test showed elevated serum IgG4 levels of 3.5 g/l (reference range, 0-2.91 g/l). Systemic work-up by computed tomography of the abdomen revealed normal pancreas. Patients preferred observation and declined systemic steroid treatment. Upon clinical follow-up until 2010, she remained asymptomatic with no symptoms or signs of sclerosing disease involving the pancreas or other major organs.

## DISCUSSION

IgG4-related sclerosing disease is a systemic condition and involves pancreas in the majority of the cases.<sup>3</sup> It can occur in many extra-pancreatic locations such as the biliary tree, salivary gland, retroperitoneum, kidneys, prostate, lungs, lymph nodes, and breasts.<sup>1,3-9</sup> Although rare, this condition can manifest as extra-pancreatic disease without pancreatic involvement.<sup>3</sup>

Serum IgG4 is a very useful marker for the diagnosis of IgG4-related sclerosing disease, which may help avoid unnecessary surgery as this condition can be effectively treated by steroids.<sup>10,11</sup> This case illustrates no individual characteristic radiological features to establish the diagnosis of IgG4-related sclerosing disease of the breast, and the diagnosis was made histologically and serologically. Nevertheless, the multiplicity of lesions with lobulated margins, and the type I enhancement curve on contrast-enhanced MRI were observed in this patient. These findings favour a benign lesion.

In conclusion, IgG4-related sclerosing disease of the breast is a rare disease that can present with bilateral breast masses. Because it is a systemic condition, it is important to look for other sites of possible involvement, using both clinical examination and radiological investigations.



**Figure 3.** Magnetic resonance imaging features of the palpable index lesion at the 9 o'clock position (arrows) of right breast. The lesion (a) is isointense on T1-weighted image; (b) is heterogenous with a hyperintense component on T2-weighted image; and (c) shows homogenous enhancement. (d) It shows a type I enhancement curve. All the other lesions in both breasts showed similar features.

## REFERENCES

1. Kamisawa T, Funata N, Hayashi Y, et al. A new clinicopathological entity of IgG4-related autoimmune disease. *J Gastroenterol.* 2003;38:982-4.
2. Yoshida K, Toki F, Takeuchi T, Watanabe S, Shiratori K, Hayashi N. Chronic pancreatitis caused by an autoimmune abnormality. Proposal of the concept of autoimmune pancreatitis. *Dig Dis Sci.* 1995;40:1561-8.
3. Kamisawa T, Okamoto A. IgG4-related sclerosing disease. *World J Gastroenterol.* 2008;14:3948-55.
4. Abraham SC, Cruz-Correa M, Argani P, Furth EE, Hruban RH, Boitnott JK. Lymphoplasmacytic chronic cholecystitis and biliary tract disease in patients with lymphoplasmacytic sclerosing pancreatitis. *Am J Surg Pathol.* 2003;27:441-51.
5. Hamano H, Kawa S, Ochi Y, et al. Hydronephrosis associated with retroperitoneal fibrosis and sclerosing pancreatitis. *Lancet.* 2002;359:1403-4.
6. Uchiyama-Tanaka Y, Mori Y, Kumura T, et al. Acute tubulointerstitial nephritis associated with autoimmune-related pancreatitis. *Am J Kidney Dis.* 2004;43:e18-25.
7. Zen Y, Harada K, Sasaki M, et al. IgG4-related sclerosing cholangitis with and without hepatic inflammatory pseudotumor, and sclerosing pancreatitis-associated sclerosing cholangitis: do they belong to a spectrum of sclerosing pancreatitis? *Am J Surg Pathol.* 2004;28:1193-203.
8. Zen Y, Kasahara Y, Horita K, et al. Inflammatory pseudotumor of the breast in a patient with a high serum IgG4 level: histologic similarity to sclerosing pancreatitis. *Am J Surg Pathol.* 2005;29:275-8.
9. Dhobale S, Bedetti C, Killian P, et al. IgG4 related sclerosing disease with multiple organ involvements and response to corticosteroid treatment. *J Clin Rheumatol.* 2009;15:354-7.
10. Erkelens GW, Vleggaar FP, Lesterhuis W, van Buuren HR, van der Werf SD. Sclerosing pancreato-cholangitis responsive to steroid therapy. *Lancet.* 1999;354:43-4.
11. Horiuchi A, Kawa S, Hamano H, Ochi Y, Kiyosawa K. Sclerosing pancreato-cholangitis responsive to corticosteroid therapy: report of 2 case reports and review. *Gastrointest Endosc.* 2001;53:518-22.