
CASE REPORT

An Unusual Cause of Spinal Cord Myelopathy

CP Ding,¹ J George,¹ K Jayarani,¹ P Jayalakshmi²

¹Department of Biomedical Imaging, and ²Department of Pathology, Faculty of Medicine, University of Malaya Medical Centre, Kuala Lumpur, Malaysia

ABSTRACT

Brown tumour (osteitis fibrosa cystica) occurring in the spine causing myelopathy is rare. This report is of a man with brown tumour of the spine, who presented with sudden backache and progressive lower limb weakness leading to a preliminary diagnosis of metastasis. He had been receiving haemodialysis for end-stage renal failure for the previous 6 years. T2-weighted magnetic resonance imaging of the spine showed a hypointense mass in the imaging sequence rather than a hyperintense mass, which is usually seen with metastasis. Histology confirmed the diagnosis of brown tumour. The presence of T2 hypointensity within the vertebral body, which was due to fibrous tissue and haemosiderin depositions, provided a clue to the diagnosis of brown tumour.

Key Words: Hyperparathyroidism; Osteitis fibrosa cystica; Spine

INTRODUCTION

The most common radiological manifestation of end-stage renal failure is renal osteodystrophy. Musculoskeletal abnormalities of renal osteodystrophy can be classified as hyperparathyroidism, osteomalacia, osteosclerosis, osteoporosis, and soft tissue and vascular calcification. Secondary hyperparathyroidism is a frequent complication of end-stage renal failure, particularly in patients receiving haemodialysis.¹⁻⁵

Brown tumour (osteitis fibrosa cystica), also known as osteoclastoma, is a lytic bony lesion seen in patients with hyperparathyroidism. Osteosarcoma is more usually associated with primary hyperparathyroidism than secondary hyperparathyroidism. The incidence of brown tumour in patients with end-stage renal failure and secondary hyperparathyroidism is 1.5%¹ to 1.7%.² Brown tumour is a benign bone lesion that typically occurs in the medullary shafts of the long bones, ribs, mandible, metacarpals, and pelvis.⁶ Spinal involvement is less common but may require emergency surgical interven-

tion to preserve neurological function and stabilisation of the spine.

CASE REPORT

A 40-year-old man with a history of haemodialysis secondary to uncontrolled hypertension and end-stage renal failure presented in 2007 with sudden onset of backache and rapidly progressive lower limb weakness. He had no bladder or bowel incontinence.

At physical examination, there was mild tenderness on palpation of the thoracic spine. Muscle tone was normal. The power of both lower limbs were slightly reduced to grade 4-5. Deep tendon reflexes, plantar responses, sensory examinations, and sphincter tone were all normal.

Laboratory tests showed a high creatinine level of 260 µmol/L (normal range, 53-106 µmol/L), high phosphate of 1.50 mmol/L (normal range, 0.74-1.52 mmol/L), low calcium of 1.98 mmol/L (normal range, 2.05-2.55 mmol/L), and high parathyroid hormone of 222.0 pmol/L (normal range 1.1-5.3 pmol/L).

Plain radiograph of the spine showed end-plate sclerosis of the vertebral bodies (Figure 1), giving rise to the 'rugger jersey' appearance seen in secondary hyperparathyroidism. A lytic lesion was present in the T11 vertebra. The posterior cortex was not well

Correspondence: Dr K Jayarani, Department of Biomedical Imaging, Faculty of Medicine, University of Malaya Medical Centre, 59100 Kuala Lumpur, Malaysia.
Tel: (60 1) 9216 4421; Fax: (60 3) 7958 1973;
E-mail: drkasthoori@hotmail.com

Submitted: 31 July 2008; Accepted: 10 November 2008.

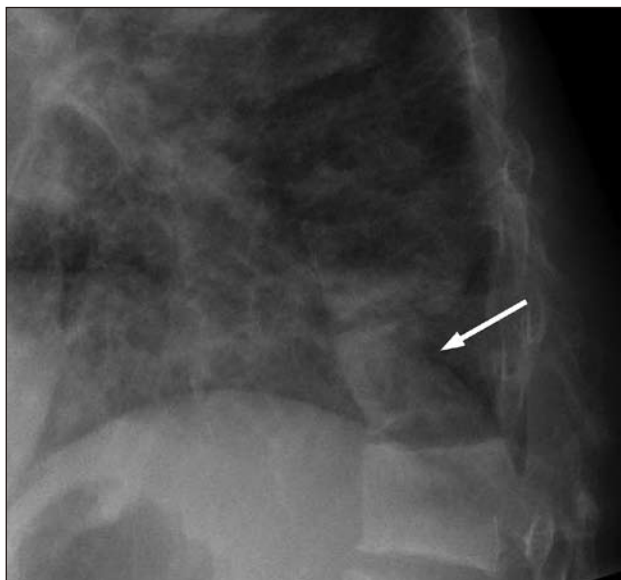


Figure 1. Lateral view of the thoracic spine showing a rugger jersey appearance at T12. A lytic lesion was seen at the T11 vertebra (arrow) with posterior vertebral body cortex erosion.

defined. Magnetic resonance imaging (MRI) of the thoracolumbar spine showed a T11 vertebral lesion with a retropulsed bony and soft tissue mass causing spinal canal stenosis and compression on the spinal cord (Figure 2). The lesion appeared isointense on T1-weighted MRI and hypointense on T2-weighted MRI, and showed enhancement following gadolinium injection. Similar

lesions were also noted in the T1 vertebra and left ala of the sacrum, although these smaller lesions did not cause substantial neurological compression.

The possibility of metastasis could not be excluded due to the patient's age and multiple lesions in the spine. The only imaging finding that was unusual for metastasis was the low signal intensity on T2-weighted MRI, in association with relative isointensity on T1-weighted MRI. Based on the clinical history, a possible diagnosis was brown tumour associated with renal failure and secondary hyperparathyroidism. A percutaneous biopsy of the T11 vertebra was performed. The pathological findings were consistent with a giant cell lesion or brown tumour (Figure 3). No histological evidence of malignancy was found. Decompressive laminectomy was performed 10 days later. The paraplegia gradually improved postoperatively. Total parathyroidectomy was performed and the parathyroid glands were examined microscopically. Low proliferative zones were subsequently autotransplanted.

DISCUSSION

Parathyroid hormone (PTH) secretion increases in response to low serum calcium concentrations and enhances the synthesis of 1,25-dihydroxyvitamin D. PTH and 1,25-dihydroxyvitamin D act together to increase

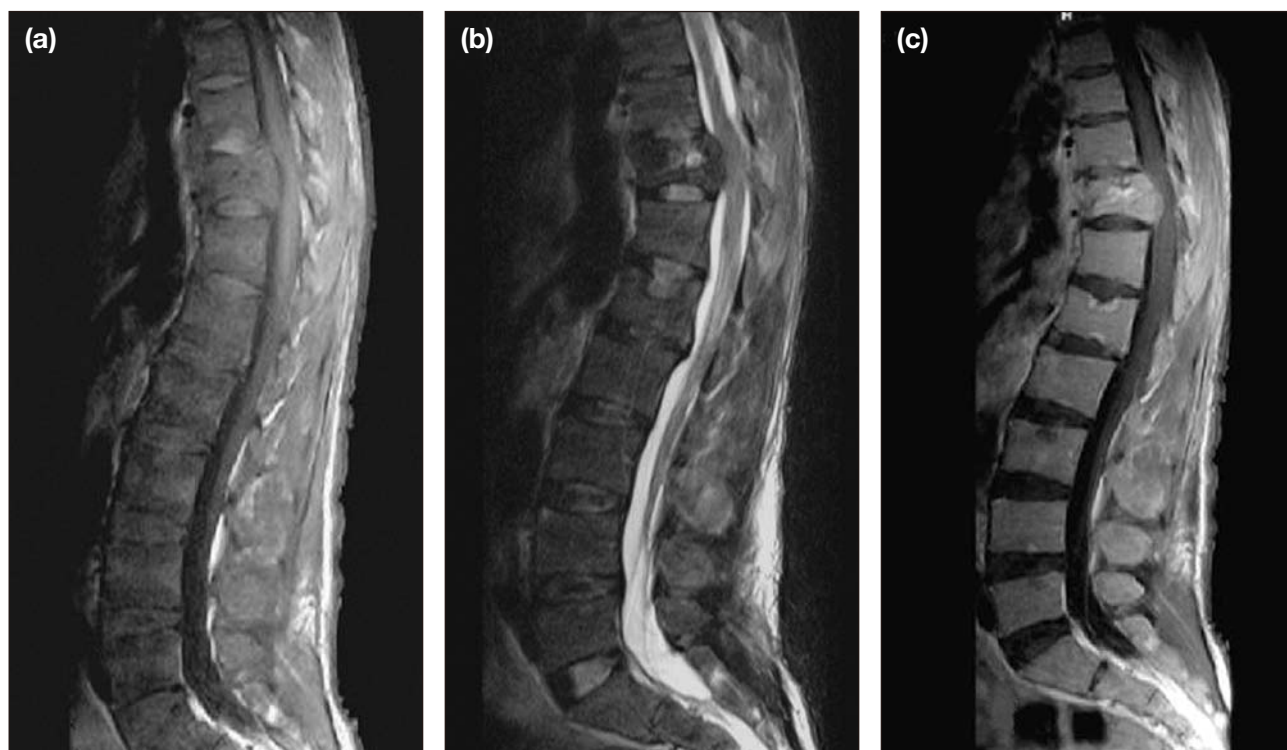

Figure 2. Sagittal (a) T1-weighted and (b) T2-weighted magnetic resonance images demonstrating a low-signal intensity mass invading the T11 vertebra and compressing the spinal cord; and (c) post-gadolinium injection image showing enhancement of the lesion.

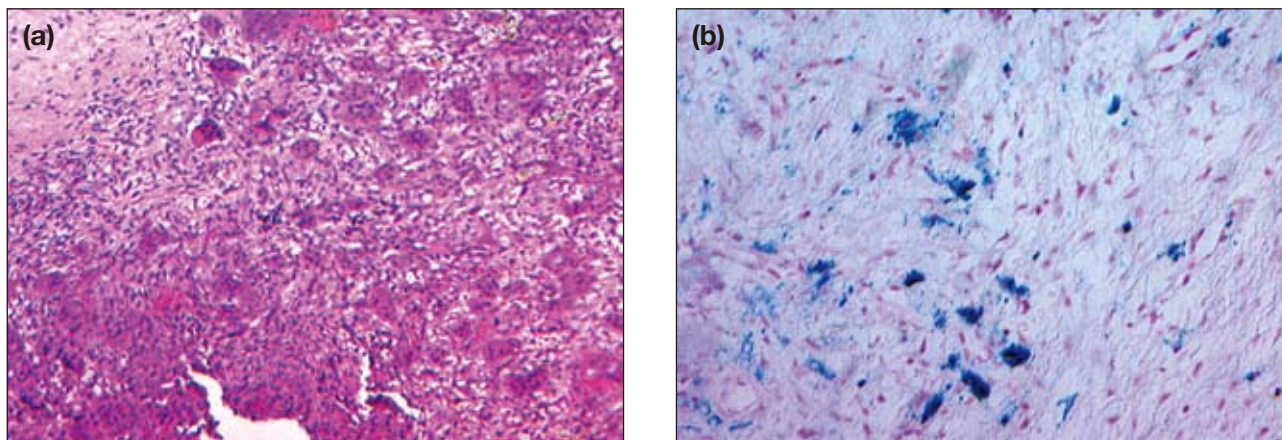


Figure 3. Histopathological specimen showing (a) histiocytes and multinucleated giant cells scattered in the fibro-vascularised stroma, with focal areas of haemorrhage compatible with brown tumor (haematoxylin and eosin stain; original magnification, x 100); and (b) haemosiderin-laden histiocytes (Prussian stain; original magnification, x 100).

calcium reabsorption in the gut and kidney and to promote osteoclastic activity and demineralization of bone.

Primary hyperparathyroidism is caused by overproduction of PTH. One or more adenomas account for the overproduction of PTH in 75% to 80% of patients with primary hyperparathyroidism, while approximately 20% are secondary to diffuse hyperplasia and carcinoma accounts for less than 2%.

Secondary hyperparathyroidism is characterised by pronounced parathyroid gland hyperplasia induced by a sustained hypocalcaemic stimulus. The consequent hypersecretion of PTH depresses calcium levels. The most important cause of secondary hyperparathyroidism is chronic renal insufficiency, which occurs in patients undergoing haemodialysis. Chronic hypocalcaemia and secondary hyperparathyroidism may also occur in vitamin D deficiency, intestinal malabsorption syndromes with inadequate absorption of vitamin D and calcium, and pseudohypoparathyroidism.^{1,3,4}

The most common presentation of renal osteodystrophy is a combination of osteomalacia, secondary hyperparathyroidism, and osteosclerosis. Several pathological changes occur in association with renal osteodystrophy; the effects of hyperparathyroidism on bone are numerous. Excess PTH results in an increase in bone breakdown by means of osteoclastic resorption with subsequent fibrous replacement and reactive osteoblastic activity. The process of bone resorption and fibrous replacement results in the characteristic radiological features of generalised bone demineralisation, resorption, cysts, brown tumours, erosion of the dental lamina dura, and pathological fractures.⁶ The bone may have

microfractures, with subsequent haemorrhage, growth of fibrous tissue, and an influx of macrophages. The resulting mass is called a brown tumour because of the brown colour of the vascular elements and blood in the mass. The spine is an uncommon site of brown tumour development.⁷⁻¹¹ To the authors' knowledge, only 12 other patients with brown tumour related to secondary hyperparathyroidism have been reported.¹²

The findings described for this patient are unusual because the T2-weighted MRI sequence demonstrated a hypointense mass rather than a hyperintense mass, which is usually seen for metastasis. The 12 previously reported patients demonstrated hyperintense masses in T2-weighted MRI scans.¹² Microscopically, these lesions are microfractures and microhaemorrhages with haemosiderin-filled macrophages and osteoclasts that become dispersed throughout the fibrous tissue in the marrow spaces. Histologically, these lesions appear as a brown colour due to haemosiderin-laden macrophages. The cells are arranged in clusters or diffusely on a background of mononuclear oval- to spindle-shaped stromal cells. The vascularity and haemosiderin deposits can be abundant.⁴ It appears that, because of the fibrous tissue and haemosiderin deposits, these masses can sometimes demonstrate hypointensity on T2-weighted images, as for this patient, which suggested brown tumour when considered with the clinical findings.

With appropriate treatment, the changes related to secondary hyperparathyroidism may resolve. Tertiary hyperparathyroidism develops in patients with long-standing secondary hyperparathyroidism, which stimulates the growth of an autonomous adenoma. As the lesions involve multiple vertebral levels, differentials such as multiple

myeloma, lymphoma, metastasis, infection such as tuberculosis and, rarely, brown tumour need to be considered. Imaging findings coupled with clinical history provide clues to the final diagnosis.

Management of renal osteodystrophy aims to control the levels of serum phosphate, calcium, and PTH. Institution of a low-phosphate diet and administration of phosphate binders, careful monitoring of dialysate calcium, and administration of oral calcium and vitamin D are the main therapeutic regimens. Definitive treatment requires total or subtotal parathyroidectomy. Surgical treatment of a vertebral brown tumour requires resection of the tumour causing neurological compression. Reconstruction surgery with bone graft or fixation is necessary if spinal instability is present.^{3,8}

REFERENCES

1. Katz AL, Hampers CL, Merrill P. Secondary hyperparathyroidism and renal osteodystrophy in chronic renal failure. *Medicine*. 1969; 48:333-74.
2. Marini M, Vidiri A, Guerrisi R, Campodonico F, Ponzio R. Progress of brown tumors in patients with chronic renal insufficiency undergoing dialysis. *Eur J Radiol*. 1992;14:67-71.
3. Pumar JM, Alvarez M, Perez-Batallon A, Vidal J, Lado J, Bollar A. Brown tumor in secondary hyperparathyroidism, causing progressive paraplegia. *Neuroradiology*. 1990;32:343.
4. Azria A, Beaudreuil J, Juquel JP, Quillard A, Bardin T. Brown tumor of the spine revealing secondary hyperparathyroidism. *Joint Bone Spine*. 2000;67:230-33.
5. Fineman I, Johnson P, Di-Patre PL, Sandhu H. Chronic renal failure causing brown tumors and myelopathy. *J Neurosurg*. 1999;90:242-6.
6. Griffiths HJ, Ennis JT, Bailey G. Skeletal changes following renal transplantation. *Diag Radiol*. 1974;113:621-6.
7. Barlow IW, Archer IA. Brown tumor of the cervical spine. *Spine*. 1993;18:936-7.
8. Bohlman ME, Kim YC, Eagan J, Spees EK. Brown tumor in secondary parathyroidism causing acute paraplegia. *Am J Med*. 1986;81:545-7.
9. Masutani K, Katafuchi R, Uenoyama K, Saito S, Fujimi S, Hirakata H. Brown tumor of the thoracic spine in a patient on long-term hemodialysis. *Clin Nephrol*. 2001;55:419-23.
10. Vandenbussche E, Schmider L, Mutschler C, Man M, Jacquot C, Augereau B. Brown tumor of the spine and progressive paraplegia in a hemodialysis patient. *Spine*. 2004;29:E251-5.
11. Gumustas O, Gumustas A, Parlak M. Thoracic myelopathy due to a vertebral brown tumor. *Eur J Radiol Extra*. 2005;56:35-8.
12. Kaya RA, Cavuşoğlu H, Tanik C, et al. Spinal cord compression caused by a brown tumor at the cervicothoracic junction. *Spine J*. 2007;7:728-32.