
CASE REPORT

Endoluminal Stent Placement in the Management of Recurrent Carotid Blowout Syndrome

JJ Kasthoori, O Nawawi

Department of Biomedical Imaging, Faculty of Medicine, University of Malaya Medical Centre, Kuala Lumpur, Malaysia

ABSTRACT

This report is of a patient with acute carotid blowout syndrome that was managed successfully with emergency placement of a covered stent. A 68-year-old man with carcinoma of the tongue had been treated surgically and underwent repeated radiotherapy for recurrence. He presented with intermittent brisk bleeding from a wound in his neck. An urgent carotid angiogram was performed and revealed a pseudoaneurysm, for which a covered stent was successfully placed.

Key Words: Aneurysm, false; Angioplasty; Carotid arteries

INTRODUCTION

Carotid blowout is an uncommon but severe complication of head and neck cancer (HNC) and its treatment.¹ In recent years, there has been marked progress in the management of carotid blowout, based on the use of angiography. This report is of a patient with acute carotid blowout syndrome that was managed successfully with emergency placement of a covered stent, which controlled the haemorrhage while preserving the carotid artery.

CASE REPORT

A 68-year-old man presented to the University of Malaya Medical Centre, Kuala Lumpur, Malaysia, in December 2004 with intermittent brisk bleeding from a wound site on the left side of his neck. He had been diagnosed with carcinoma of the tongue 3 years previously and had undergone radical neck resection and repeated radiotherapy for recurrence. A computed tomography (CT) scan 2.5 years later showed an ulcer crater at the left lower neck with soft tissue swelling surrounding the left carotid sheath, which corresponded to post-radiation changes with the possibility of disease progression.

During the current admission, he was referred to the radiology department for an urgent angiogram of the left carotid vessels with a view to intervention. Prior to the angiogram, the bleeding was temporarily controlled by a pressure dressing and his condition was stabilised with 3 units of blood and 5 units of fluid resuscitation.

The diagnostic tests performed initially revealed moderate narrowing of the common carotid artery (CCA) with an associated 4- x 8-mm pseudoaneurysm at the mid-CCA (Figure 1a). No active bleeding was seen during the angiography. There was mild to moderate regular stenosis of the proximal left internal carotid artery and external carotid artery, features of which were consistent with post-radiation changes (Figure 1b). The pseudoaneurysm was crossed with a guide wire, and a 6- x 38-mm peripheral Jostent (Jomed, Rangendingen, Germany) was deployed across the pseudoaneurysm in the CCA via a long sheath. The choice of stent was based on its availability and the diameter and length of the target lesion. Prophylactic heparin was not administered. Angiogram post-stenting showed immediate occlusion of the pseudoaneurysm with good distal run off (Figure 2).

The patient was discharged after 2 days and given plavix 75 mg daily. After 2 weeks, he had a recurrent bleed from the wound on the left side of his neck. An urgent repeat angiogram showed active extravasation just

Correspondence: Dr JJ Kasthoori, Department of Biomedical Imaging, Faculty of Medicine, University of Malaya Medical Centre, 59100 Kuala Lumpur, Malaysia.

Tel: 0192164421; Fax: (60 3) 7958 1973;

E-mail: drkasthoori@hotmail.com

Submitted: 7 June 2007; Accepted: 13 July 2007.

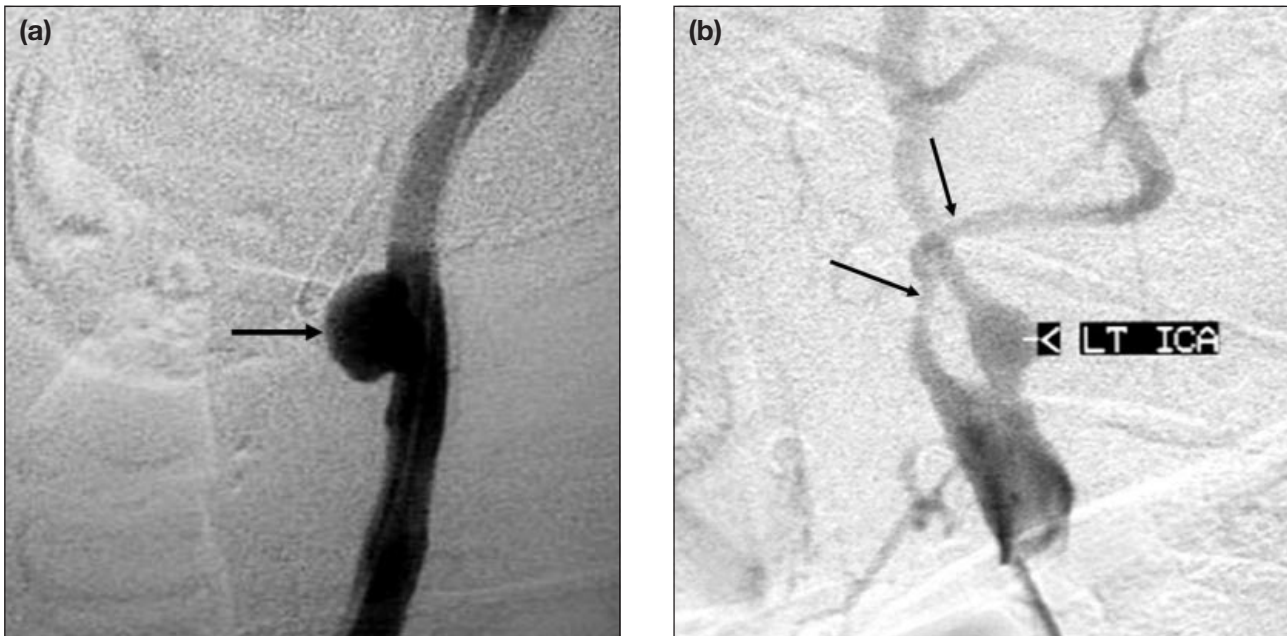


Figure 1. Angiogram of (a) the left common carotid artery revealed a large pseudoaneurysm (arrow) measuring 4 x 8 mm; and (b) irregular stenosis (arrows) of the proximal internal carotid artery and external carotid artery, consistent with post-radiation changes.

above the distal part of the previously deployed stent due to a small pseudoaneurysm (Figure 3a). The existing stent graft was in situ and patent. Subsequently, another 10- x 70-mm Wallstent (Boston Scientific, Natick, USA) was successfully deployed through the existing stent. Angiogram post-stenting showed cessation of bleeding and obliteration of the pseudoaneurysm

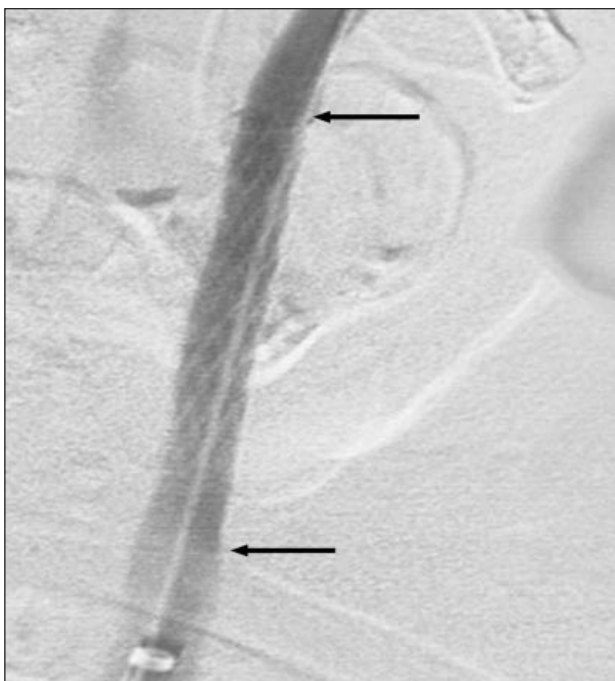

Figure 2. Left common carotid angiogram after deploying the stent (arrows) showed good distal run off and complete obliteration of the pseudoaneurysm.

(Figure 3b). Following the restenting procedure, the patient had no further episodes of rebleeding and was neurologically intact. However, after 1 month, the patient returned with an infected wound of the neck and anaemia, for which he received blood transfusion and antibiotics. Unfortunately, he died 1 month later due to disease progression.

DISCUSSION

Carotid blowout was first described in 1962. Carotid blowout is an uncommon complication of HNC, occurring in 4.3% of patients with such cancers.¹ Radiation therapy, radical resection, flap necrosis with carotid exposure, wound infection, pharyngocutaneous fistula, and recurrent or persistent carcinoma have all been implicated as aetiologic factors of carotid blowout syndrome. Previous irradiation adds a 7.6-fold increased risk for developing carotid blowout.²

Carotid blowout is now considered to be a syndrome, with clinical manifestations ranging from acute haemorrhage to asymptomatic exposure of a carotid artery. As a result, carotid blowout syndrome can present as 1 of 3 separate entities: threatened, impending, or acute. The diagnostic approach is guided by the clinical presentation.^{1,2}

With the advent of new imaging techniques, threatened carotid blowout is characterized by radiological findings consistent with neoplastic invasion of the carotid

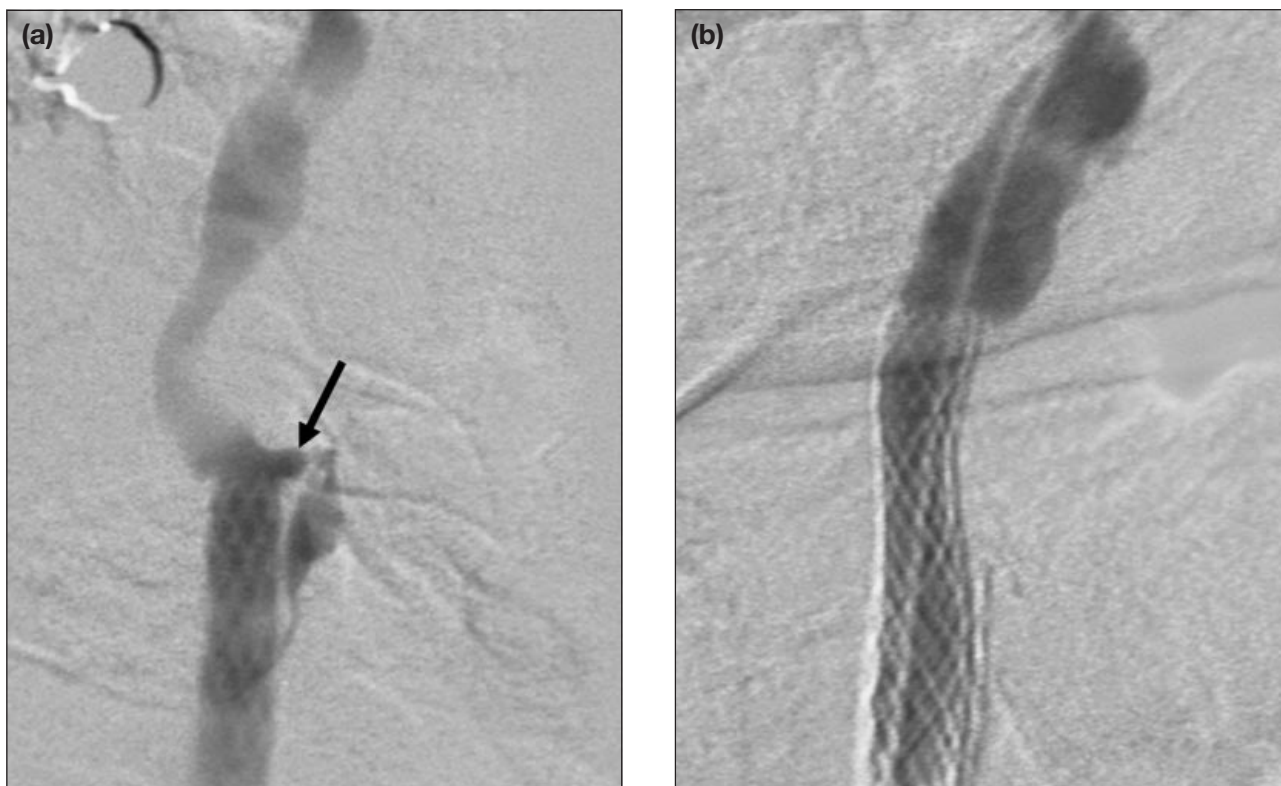

Figure 3. (a) Left carotid artery angiogram performed during the second admission showed a small leaking pseudoaneurysm (arrow) distal to the previously deployed stent graft — excellent flow was seen through the existing stent with occlusion of the pseudoaneurysm; and (b) check angiogram after deployment of a second stent graft shows complete occlusion of the pseudoaneurysm.

vessel with non-haemorrhagic pseudoaneurysm visualised on angiography. The findings suggest an inevitable haemorrhage in the immediate future if no action is taken. Impending carotid blowout occurs as a transcervical or transoral haemorrhage, typically from a pseudoaneurysm bleeding through a surgical wound or fistula that resolves either spontaneously or with pressure. In contrast, acute carotid blowout is a haemorrhage that cannot be stopped only by packing or pressure, as in this patient.

Historically, carotid blowout has been associated with 40% mortality and 60% neurological morbidity.^{1,2} The initial management includes exploration of the neck and ligation of the vessels. Inherent difficulties are encountered when operating on an unstable patient in an infected and often tumour-laden wound. Furthermore, the complication rate for cerebral ischemia is high.

Multiple reports during the past 2 decades suggest a marked reduction in the morbidity rate to 0% to 8% and mortality of 0%.^{1,2} This reduction is due to the advent of various new endovascular techniques such as carotid occlusion by coils, detachable balloons, or endovascular stents, coupled with angiography. However,

angiography has a complication rate of 8.50%, and the incidence of neurological complications is 0.60%, with permanent deficits reported in 0.33% of patients.¹

Endovascular techniques have their advantages and disadvantages. Permanent balloon occlusion and coil embolisation of an affected artery was initially described in 1984.³ Although haemorrhage may be quickly arrested, recurrent bleeding and a delayed transient ischaemia rate of 15% to 20% with neurological sequelae has been reported.^{4,5}

Due to this limitation, an alternative strategy for the management of carotid blowout syndrome is to reconstruct the damaged artery using endovascular stents. The recent experience reported by Lesley et al, of 12 patients with stent-assisted endovascular reconstruction for the treatment of carotid blowout has been very favourable.² These authors reported that only 1 case (8%) of procedure-related transient ischaemia occurred, and no deaths or permanent morbidity attributable to endovascular reconstruction occurred. These low complication rates are comparable with those reported in association with endovascular stent placement of carotid atherosclerotic stenosis.

Unfortunately, if stents are placed in a contaminated wound where the stents may be exposed, as is usually the case in an emergency situation, stent infection is almost inevitable. Occlusion or recurrent haemorrhages may also occur.

Although significant advances have been made in the management of carotid blowout syndrome, the principles of the initial management remain the same: control of the airway, control of bleeding with pressure, and fluid resuscitation.

In an emergency situation, management by placement of a covered stent is considered most effective as it allows immediate exclusion of the pseudoaneurysm with preservation of the carotid artery and cessation of haemorrhage. The patient described here illustrates the most important therapeutic challenges with which interventional radiologists may be confronted when treating patients with carotid blowout syndrome. Although not the stent of choice, the Jostent was used for this patient because of its availability. A secondary goal of this approach was to provide additional structural support to a long segment of the diseased carotid system in an attempt to prevent rupture at other sites. This latter hypothesis is based on the knowledge of the pathology of carotid blowout syndrome, in which there is typically extensive and multifocal radiation fibrosis, medial necrosis, inflammatory infiltration, loss of adventitia, secondary atherosclerosis, and lack of external supportive tissues.⁵

An alternate approach may have been to attempt to control the haemorrhage with placement of an occlusion balloon, but this was restricted by the fact that there

was a wide-necked pseudoaneurysm with secondary rupture. This technique may have caused enlargement of the neck or rupture from an additional site. Endovascular stenting is an effective temporary solution, until a more permanent solution such as extra-anatomic arterial bypass or flap coverage of the involved artery can take place under more ideal circumstances.^{6,7}

With adherence to the long-established principles of management and the use of newer techniques of interventional radiology, carotid artery blowout syndrome can be successfully managed without the attendant morbidity and mortality of cerebral ischaemia for these patients.

REFERENCES

1. Cohen J, Rad I. Contemporary management of carotid blowout. *Curr Opin Otolaryngol Head Neck Surg.* 2004;12:110-5.
2. Lesley WS, Chaloupka JC, Weigele JB, Mangla S, Dogar MA. Preliminary experience with endovascular reconstruction for the management of carotid blowout syndrome. *AJNR Am J Neuroradiol.* 2003;24:975-81.
3. Osguthorpe JD, Hungerford GD. Transarterial carotid occlusion: case report and review of the literature. *Arch Otolaryngol.* 1984;110:694-6.
4. Chaloupka JC, Putman CM, Citardi MJ, Ross DA, Sasaki CT. Endovascular therapy for the carotid blowout syndrome in the head and neck surgical patients. *AJNR Am J Neuroradiol.* 1996;17:843-52.
5. Bush RL, Lin PH, Dodson TF, Dion JE, Lumsden AB. Endoluminal stent placement and coil embolization for the management of carotid artery pseudoaneurysms. *J Endovasc Ther.* 2001;8:53-61.
6. Macdonald S, Gan J, McKay AJ, Edwards RD. Endovascular treatment of acute carotid blow-out syndrome. *J Vasc Interv Radiol.* 2000;11:1184-8.
7. Saatci I, Cekirge SH, Ozturk MH, et al. Treatment of internal carotid artery aneurysms with a covered stent: experience in 24 patients with mid-term follow-up results. *AJNR Am J Neuroradiol.* 2004;25:1742-9.